

Curriculum Vitae

Francesco Cultrera

May, 20<sup>th</sup>, 2023

*Francesco Cultrera*

## Personal details

### Full name

Francesco Cultrera

### Date and place of birth

January 29<sup>th</sup>, 1970, Catania, Italy

### Marital status

Married (no children). Name of spouse: Elisa Briccola

### Current address

Via Guidi di Calisese 329, 47521, Cesena (FC), Italy

### Phone

Mobile: +39 333/4136880

Work: +39 0547/ 352916

Fax: +39 0547/ 352914

[cultrera.ciccio70@gmail.com](mailto:cultrera.ciccio70@gmail.com)

[francesco.cultrera@auslromagna.it](mailto:francesco.cultrera@auslromagna.it)

## Additional information

Knowledge of foreign languages: English (good knowledge) and "basic" Spanish

Computer skills: both Windows and Macintosh operative systems

Personal interests: I enjoy playing piano (classical music) and listening to jazz music. I practice some outdoor sports (jogging, cycling) with regularity.

## **Education and qualifications**

March 1996:

graduated in medicine, University of Catania, Italy

June 1996

professional registration (college of physicians and surgeons, Catania, n° 11216)

September 2002

qualified as a neurosurgeon, Residency Program in Neurosurgery, University of Catania, Italy

## **Career history**

September 1996- February 1997

internship at the division of neurosurgery, University of Catania

March 1997- September 2002

resident at the school of neurosurgery, University of Catania

October 2000- January 2001; October 2001- January 2002

division of neurosurgery, "Cannizzaro" hospital, Catania, Italy.

Treatment of degenerative and post-traumatic vertebral instability.

February 2002

division of neurosurgery "IRCCS Casa Sollievo della Sofferenza", S. Giovanni Rotondo (FG), Italy.

Endovascular treatment of intracranial aneurysms and carotid artery stenosis, radiosurgery (LINAC) for brain metastases.

February 2001- July 2001; May 2002- August 2002

division of neurosurgery/ neurotraumatology (WHO Collaborating Centre on Neurotrauma), "Bufalini" hospital, Cesena, Italy.

Management of head trauma patients (use of teleradiology-CT image-transmission, neurotraumatology surgery, ICP-monitoring).

Peripheral nerves surgery.

January-June 2003

Division of neurosurgery, "Bufalini" hospital, Cesena, Italy.

Management of CNS tumours.

August 2003- June 2005

Staff neurosurgeon at the neurosurgery unit, "Clinica Villa Azzurra", Siracusa, Italy. A 15-bed (three in ICU) unit, serving an area of about 300.000 inhabitants.

September 20th December 10th 2004

observership at the department of neurosurgery, M.D. Anderson Cancer Center. Houston (TX), U.S.A.

Intraoperative mapping techniques and surgery of tumors in brain eloquent areas.

July- October 2005

Fellow in complex spinal surgery. Department of neurosurgery, Beaumont hospital, Dublin (EIRE).

Instrumentation procedures for degenerative spinal deformity, spinal tumor surgery.

## Current position

### November 2005- today

Staff neurosurgeon. Division of neurosurgery, "Bufalini" hospital, Cesena, Italy. A 31-bed (+14 in ICU) unit serving an area of about 1.000.000 inhabitants (doubling in summer). Referral trauma center for the whole area. About 1600 surgeries performed per year.

From November 2019 onward: senior spinal surgeon, referring physician for complex spinal pathology.

## Surgical experience

About 5000 procedures as a first surgeon.

In the last years I developed a particular interest in spine surgery (which accounts for  $\approx 60\%$  of my caseload: either uninstrumented or instrumented procedures, for degenerative, neoplastic and traumatic pathology).

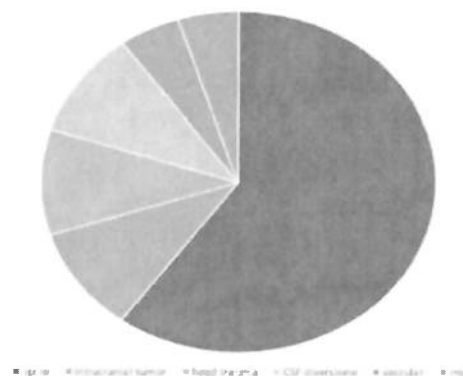
Intracranial tumors account for  $\approx 10\%$  of my activity (tumor resection via craniotomy, cortical mapping and stealth-assisted excision and frameless procedures for biopsy).

Procedures for head trauma  $\approx 10\%$  (emergency surgery for traumatic hematomas, ICP monitor, treatment of malignant brain swelling, chronic subdural hematoma and delayed surgery for repair of skull defects and complex cranial fractures).

CSF-diversion procedures  $\approx 10\%$  (shunting, endoscopy and decompression for Chiari malformation and/or siringomyelia).

Vascular diseases  $\approx 5\%$ : spontaneous brain hemorrhage, vascular malformations  
Infectious pathology (intracranial abscess, empyema)  $\approx 3\%$

Miscellaneous (revision surgery for post-operative fistulas, etc.)  $\approx 2\%$



## **Membership, main courses' attendance, publications**

AOSpine member (no. 838146)

Volunteer member of the Foundation for International Education in Neurosurgery (FIENS) and member of Intersurgeon.org for promoting neurosurgery in underserved countries.

---

December 11-12, 2008

Cervical spine: choosing the right solution. Dublin, EIRE

February 10-12, 2009

Posterior instrumentation for lumbar spine degenerative pathology (cad lab). Leiden, the Netherlands

April 28-29, 2010

Techniques for arthrodesis of the cranio-cervical junction (live surgery). Bologna, Italy

September 8-9, 2011

Minimal invasive surgical techniques in the degenerative lumbar spine. Instructional course (cad lab). Barcelona, Spain

October 27-28, 2014

Spine surgery: minimally invasive vs. open techniques (cad lab). Wien, Austria

June 15, 2015

Lateral and anterior approaches in the thoracolumbar spine (cad lab). Basel, Switzerland

April 6-10, 2016

13th neuroendoscopy fellowship. NSCB Medical College (cad lab + live surgery). Jabalpur (MP), India

April 25-29, 2016

Approaches to cavernous sinus: skull base craniotomy and neuroendoscopy (cad lab). AAIMS, New Delhi, India

March 29-31, 2017

Seventh international course basic neurosurgical approaches and microdissection. Arezzo, Italy

September 7-8, 2017

AOSpine advanced level specimen course-Anterior spine surgery and approaches. Innsbruck, Austria

September 7-8, 2018

Lateral techniques cadaveric training program. Verona, Italy

---

Calcified Epidural Hematoma after Conservative Treatment of Acute Epidural Hematoma in the Pediatric Population: A Systematic Review.

D'Andrea M, Mongardi L, Cultrera F, Fuschillo D, Peraio S, Roblot P, Musio A, Tosatto L, Giordano F. *Pediatr Neurosurg.* 2022;57(6):389-395. doi: 10.1159/000527241

FUSE-ML: development and external validation of a clinical prediction model for mid-term outcomes after lumbar spinal fusion for degenerative disease.

Staartjes VE, Stumpo V, Ricciardi L, Maldaner N, Eversdijk HAJ, Vieli M, Ciobanu-Caraus O, Raco A, Miscusi M, Perna A, Proietti L, Lofrese G, Dughiero M, Cultrera F, Nicassio N, An SB, Ha Y, Amelot A, Alcobendas I, Viñuela-Prieto JM, Gandía-González

ML, Girod PP, Lener S, Kögl N, Abramovic A, Safa NA, Laux CJ, Farshad M, O'Riordan D, Loibl M, Mannion AF, Scerrati A, Molliqaj G, Tessitore E, Schröder ML, Vandertop WP, Stienen MN, Regli L, Serra C. *Eur Spine J*. 2022 Oct;31(10):2629-2638. doi: 10.1007/s00586-022-07135-9.

Anterior Dural Tear in Thoracic and Lumbar Spinal Fractures: Single-Center Experience with Coating Technique and Literature Review of the Available Strategies.  
Lofrese G, Visani J, Cultrera F, De Bonis P, Tosatto L, Scerrati A. *Life (Basel)*. 2021 Aug 25;11(9):875. doi: 10.3390/life11090875. PMID: 34575024

Use of the SpineJack direct reduction for treating type A2, A3 and A4 fractures of the thoracolumbar spine: a retrospective case series.  
Lofrese G, Ricciardi L, De Bonis P, Cultrera F, Cappuccio M, Scerrati A, Martucci A, Musio A, Tosatto L, De Iure F. *J Neurointerv Surg*. 2022 Sep;14(9):931-937. doi: 10.1136/neurintsurg-2021-017682.

Surgical treatment of metastatic pheochromocytomas of the spine: a systematic review.  
Visani J, Mongardi L, Cultrera F, Bonis P, Lofrese G, Ricciardi L, Scerrati A. *J Integr Neurosci*. 2021 Jun 30;20(2):499-507. doi: 10.31083/j.jin2002053. PMID: 34258952

Surgical Treatment of Diffuse Idiopathic Skeletal Hyperostosis (DISH) Involving the Cervical Spine: Technical Nuances and Outcome of a Multicenter Experience.  
Lofrese G, Scerrati A, Balsano M, Bassani R, Cappuccio M, Cavallo MA, Cofano F, Cultrera F, De Iure F, Biase FD, Donati R, Garbossa D, Menegatti M, Olivi A, Palandri G, Raco A, Ricciardi L, Spena G, Tosatto L, Visani J, Visocchi M, Zona G, De Bonis P. *Global Spine J*. 2022 Oct;12(8):1751-1760. doi: 10.1177/2192568220988272. PMID: 33590802

Long-term outcomes of endoscopic third ventriculostomy for Blake's pouch cyst in adults.  
D'Andrea M, Mongardi L, Cultrera F, Lenge M, Tosatto L, Giordano F. *Clin Neurol Neurosurg*. 2021 Mar;202:106502. doi: 10.1016/j.clineuro.2021.106502.

Endoscopic third ventriculostomy for the treatment of Blake's pouch cyst in adulthood.  
Mongardi L, D'Andrea M, Tosatto L, Volpin M, Cultrera F. *Acta Neurol Belg*. 2022 Apr;122(2):537-539. doi: 10.1007/s13760-020-01591-0.

Ct guided reference markers for spinal dorsal lesions: A safe and valuable tool impacting intraoperative localization time.  
Mongardi L, Visani J, Mantovani G, Olivetti ME, Scerrati A, Cultrera F, Ricciardi L, De Bonis P, Cavallo MA, Lofrese G. *J Clin Neurosci*. 2021 Feb;84:97-101. doi: 10.1016/j.jocn.2020.11.039.

Odontoid screw placement for Anderson type II odontoid fractures: how do duration from injury to surgery and clinical and radiological factors influence the union rate? A multicenter retrospective study.  
Ricciardi L, Trungu S, Scerrati A, De Bonis P, Rustemi O, Mazzetto M, Lofrese G, Cultrera F, Barrey CY, Di Bartolomeo A, Piazza A, Miscusi M, Raco A. *J Neurosurg Spine*. 2020 Oct 2;1-5. doi: 10.3171/2020.6.SPINE20318

Chylothorax in spine fractures: A rarely reported complication? Literature review with an example case.

Lofrese G, Cultrera F, Visani J, Scerrati A, Mongardi L, Donati R, Tosatto L, De Bonis P. J Trauma Acute Care Surg. 2020 Nov;89(5):e140-e146. doi: 10.1097/TA.0000000000002896.PMID: 32769951

Spontaneous Repositioning of Isolated Blow-In Orbital Roof Fracture: Could Wait and See Be a Strategy in Asymptomatic Cases?

Lofrese G, Mongardi L, De Bonis P, Scerrati A, Nicassio N, Cultrera F. J Craniofac Surg. 2020 May/Jun;31:e263-e266.doi:10.1097/SCS.0000000000006231.PMID: 32049903

Intraoperative Doppler ultrasound as a means of preventing vertebral artery injury during Goel and Harms C1-C2 posterior arthrodesis: technical note.

Lofrese G, Cultrera F, Visani J, Nicassio N, Essayed W, Donati R, Cavallo MA, De Bonis P. J Neurosurg Spine. 2019 Aug 16;1-7. doi: 10.3171/2019.5.SPINE1959. PMID: 31419805

Functional Outcome of Elderly Patients Treated for Odontoid Fracture: A Multicenter Study.

De Bonis P, Iaccarino C, Musio A, Martucci A, De Iure F, Donati R, Cultrera F, Tosatto L, Servadei F, Alesi D, Cavallo MA, Ghadirpour R, Molinari F, Lofrese G. Spine (Phila Pa 1976). 2019 Jul 1;44(13):951-958. doi: 10.1097/BRS.0000000000002982. PMID: 31205176

Type II odontoid fracture in elderly patients treated conservatively: is fracture healing the goal?

Lofrese G, Musio A, De Iure F, Cultrera F, Martucci A, Iaccarino C, Essayed W, Ghadirpour R, Servadei F, Cavallo MA, De Bonis P. Eur Spine J. 2019 May;28(5):1064-1071. doi: 10.1007/s00586-019-05898-2.

Spontaneous intracranial hypotension due to sacral diverticula: Two-case history and a pocket-sized review.

Cultrera F, Lofrese G, Nasi MT. Neurocirugia (Astur : Engl Ed). 2019 Sep-Oct;30(5):228-232. doi: 10.1016/j.neucir.2018.06.003.

Vertebral body spread in thoracolumbar burst fractures can predict posterior construct failure.

De Iure F, Lofrese G, De Bonis P, Cultrera F, Cappuccio M, Battisti S. Spine J. 2018 Jun;18(6):1005-1013. doi: 10.1016/j.spinee.2017.10.064.

Spinal angioliopoma.

Cultrera F, Cozzi F, Lofrese G, Riccioni L, Cataldi ML, Tosatto L. J Neurosurg Sci. 2019 Feb;63(1):98-99. doi: 10.23736/S0390-5616.17.04024-3.

Unstable thoracic spine fracture with aortic encroachment: A potentially fatal association and a suggested treatment.

Cultrera F, Gamberini E, Iacono G, Turicchia GU, Agnoletti V, Tosatto L. Int J Surg Case Rep. 2017;39:181-184. doi: 10.1016/j.ijscr.2017.08.015.

Surgical treatment of intraforaminal/extraforaminal lumbar disc herniations: Many approaches for few surgical routes.

Lofrese G, Mongardi L, Cultrera F, Trapella G, De Bonis P. Acta Neurochir (Wien). 2017 Jul;159(7):1273-1281. doi: 10.1007/s00701-017-3198-9.

Unilateral oculomotor nerve palsy: unusual sign of hydrocephalus.

Cultrera F, D'Andrea M, Battaglia R, Chiericato A. J Neurosurg Sci. 2009 Jun;53(2):67-70.PMID: 19546847

Delayed post-traumatic frontal sinus mucopyocele presenting with meningitis.

Cultrera F, Giuffrida M, Mancuso P. J Craniomaxillofac Surg. 2006 Dec;34(8):502-4. doi: 10.1016/j.jcms.2006.07.863. PMID: 17157027

Two-stage treatment of a tectal ganglioglioma: endoscopic third ventriculostomy followed by surgical resection.

Cultrera F, Guiducci G, Nasi MT, Paioli G, Frattarelli M. J Clin Neurosci. 2006 Nov;13(9):963-5. doi: 10.1016/j.jocn.2005.09.011. PMID: 16914316

Central neurocytoma of the fourth ventricle. Case history.

Cultrera F, Giuffrida M, Guiducci G, Cerasoli S, Frattarelli M. J Neurosurg Sci. 2005 Sep;49(3):125-8.PMID: 16288195

Isolated glossopharyngeal and vagus nerves palsy due to fracture involving the left jugular foramen.

Alberio N, Cultrera F, Antonelli V, Servadei F. Acta Neurochir (Wien). 2005 Jul;147(7):791-4; discussion 794. doi: 10.1007/s00701-005-0547-x.PMID: 15891807

Neurological deterioration after head trauma in patients with colloid cysts of the 3rd ventricle. Two case histories.

Cultrera F, Parisi G, Platania N, Consoli V, Albanese V. J Neurosurg Sci. 2004 Jun;48(2):67-70.PMID: 15550901

Spinal epidural hematoma following coronary thrombolysis. A case report.

Cultrera F, Passanisi M, Giliberto O, Giuffrida M, Mancuso P, Ventura F. J Neurosurg Sci. 2004 Mar;48(1):43-7.PMID: 15257265

Overlap among neurocutaneous syndromes. Observations on encephalocraniocutaneous lipomatosis.

Cultrera F, Guarnera F, Giardina MC. Minerva Pediatr. 2004 Apr;56(2):219-22.PMID: 15249907

Hemorrhagic unilateral moyamoya: report of one case.

Cultrera F, Giuffrida M, Alberio N, Chiaramonte I. Neurologia. 2004 Jun;19(5):277-9.PMID: 15150713

Growing-fracture of the orbital roof with post-traumatic encephalocele in an adult patient. Case report.

Giuffrida M, Cultrera F, Antonelli V, Campobassi A, Servadei F. J Neurosurg Sci. 2002 Dec;46(3-4):131-4.PMID: 12690337

Integration of image transmission into a protocol for head injury management: a preliminary report.

Servadei F, Antonelli V, Mastrilli A, Cultrera F, Giuffrida M, Staffa G. Br J Neurosurg. 2002 Feb;16(1):36-42. doi: 10.1080/02688690120114255.PMID: 11926463