

81 aa, Donna

GENERALITA'

- ▣ H 160 cm, Peso 65 Kg, BMI 25
- ▣ VFG 41mL/min

ANAMNESI GENERALE

- ▣ Fattori di rischio: Iperensione arteriosa, Ipercolesterolemia (Statine)
- ▣ Stenosi aortica in FUP > sintomatica per dispnea da sforzo



ECOCARDIOGRAMMA

- ▶ Ventricolo sinistro di dimensioni nei limiti, ipertrofia a prevalenza settale moderata, FE 65%.
- ▶ Valvola aortica calcifica; stenosi di grado severo (LVOT 1.9 cm, grad max/med 71/44 mmHg, AVAf 0.7 cm², AVA/BS 0.45). Minima insufficienza.
- ▶ Insufficienza mitralica degenerativa di grado lieve.
- ▶ Minimo scollamento pericardico anteriore al ventricolo dx di nessun impatto emodinamico.
- ▶ VCI non dilatata
- ▶ Ectasia aorta ascendente (37 mm).

PROVA PRATICA. N.2



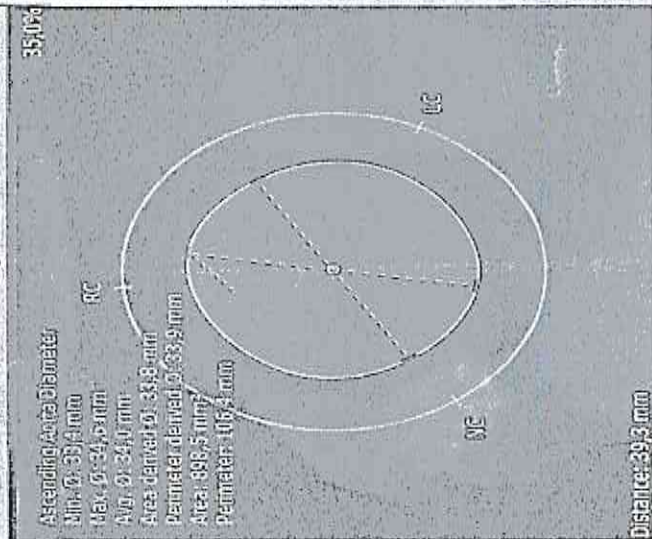


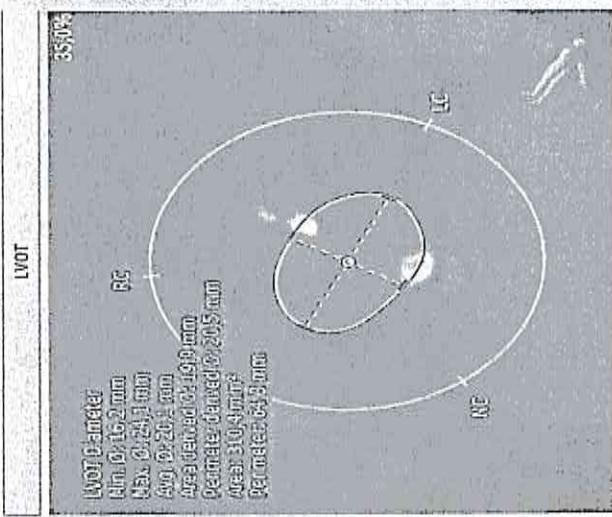
D. 
2/5


ANGIO TC Agatston 3054

PROVA PRATICA N.2

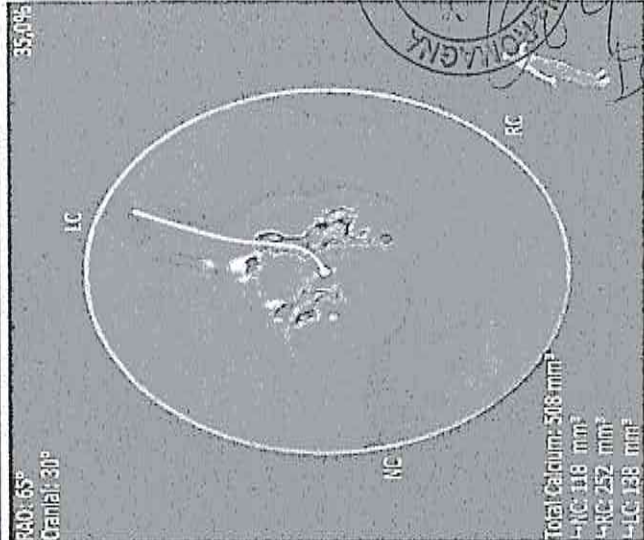






3/5
 [Handwritten initials]



ANGIO TC

Agatston 3054



PROVA

FRATICA N.2



PROVA PRATICA N.2



5/5

ANGIO TC

