

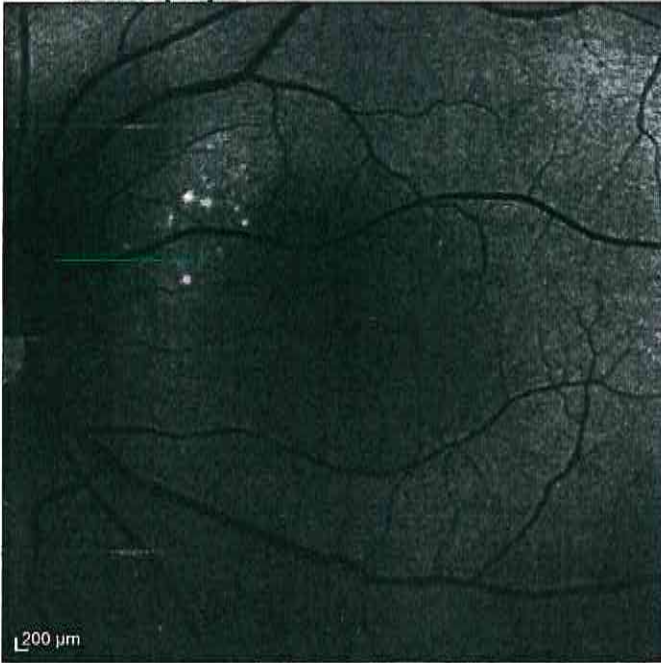ALLEGATO 1

Patient: xxx, SIMONE
Patient ID: ---
Diagnosis: ---

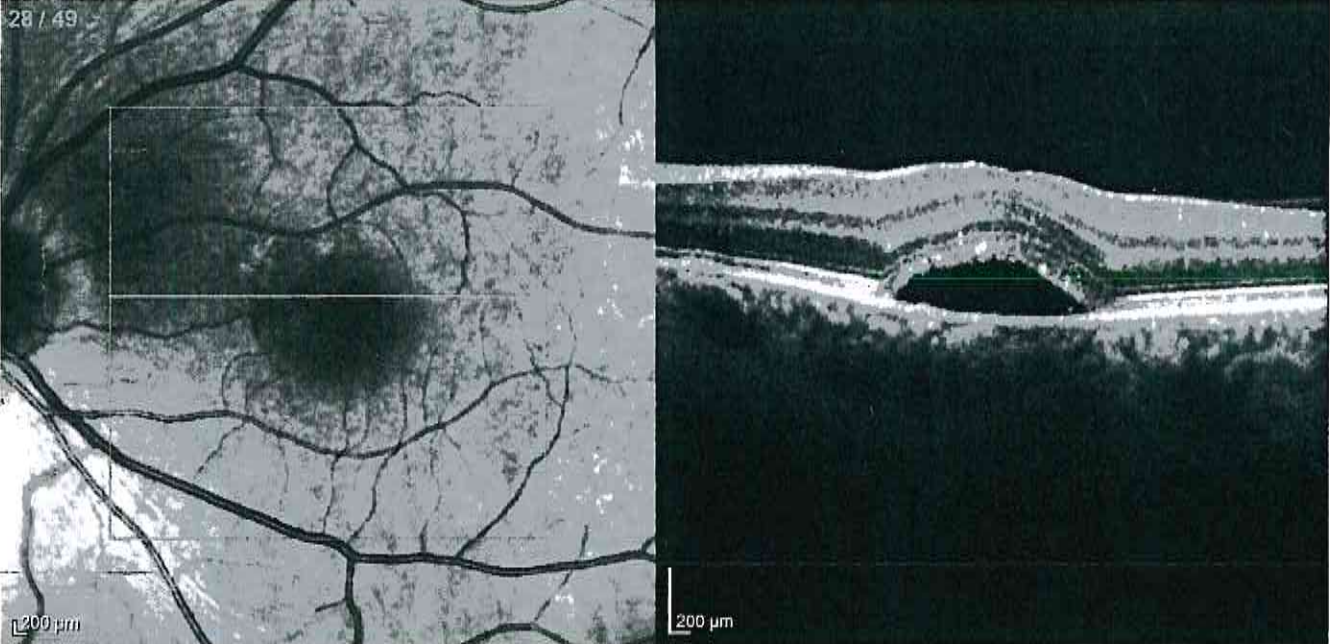
DOB: 10/lug/1977 Sex: M
Exam.: 01/lug/2020
Comment: disturbi del visus da circa un mese

OS

BAF 30° ART [HS]



IR 30° ART + OCT 20° (5.8 mm) ART (18) Q: 29 [HS]



Notes:

Date: 07/05/2024

Signature:

ALEGATO 2

Topography

ID: 04111995

Name: xxx - 4/11/1995

Exam Date: 15/Apr./2024 10:55:07 QS:OK

Comment: Peggioramento del visus



Keratometric

Ks	55.73 D	@ 70°
Kf	51.51 D	@ 160°
CYL	4.22 D	@ 70°
AvgK	53.62 D	
AA (10mm)	100.0 %	
ACCP	55.92 D	
Ecc (9.0mm)	1.06	

Posterior

Ks	-9.50 D	@ 80°
Kf	-8.35 D	@ 170°
CYL	1.15 D	@ 170°
AvgK	-8.92 D	
AA (10mm)	99.7 %	
Ecc (9.0mm)	1.23	

Real

Ks	52.98 D	@ 67°
Kf	49.25 D	@ 157°
CYL	3.73 D	@ 67°
AvgK	51.12 D	
AA (10mm)	99.7 %	
ACCP	53.62 D	

Pachymetry

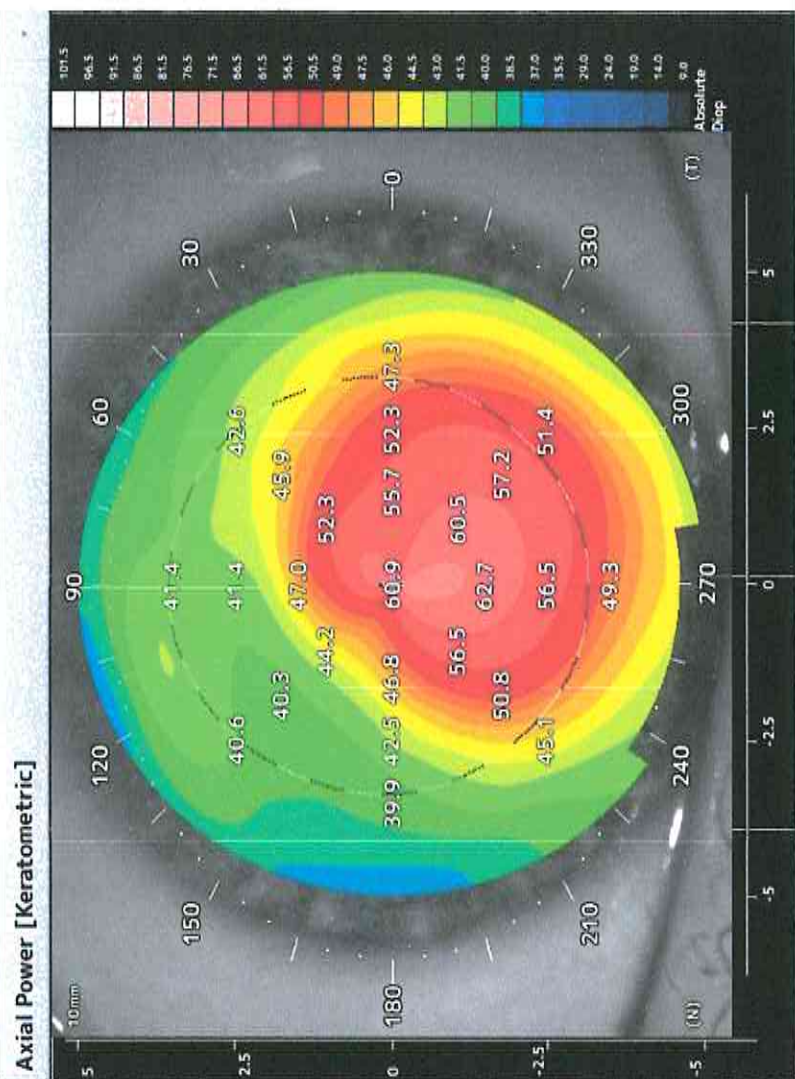
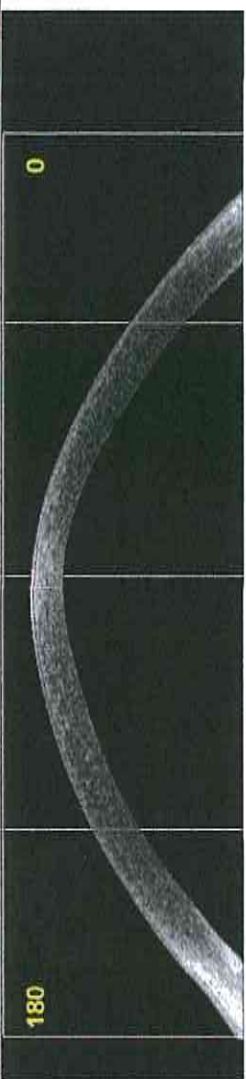Apex	477 um
Thinnest	426 um
	(0.50 , -0.75) mm

Pupil D

	6.68 mm
	(0.00 , 0.18) mm

ACD [Endo.]

	3.23 mm
ESI	95 %



ALLEGATO 3

2D Analysis

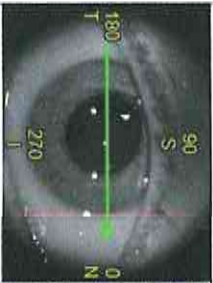
ID: 01081952

Name: xxx - 14/5/1943

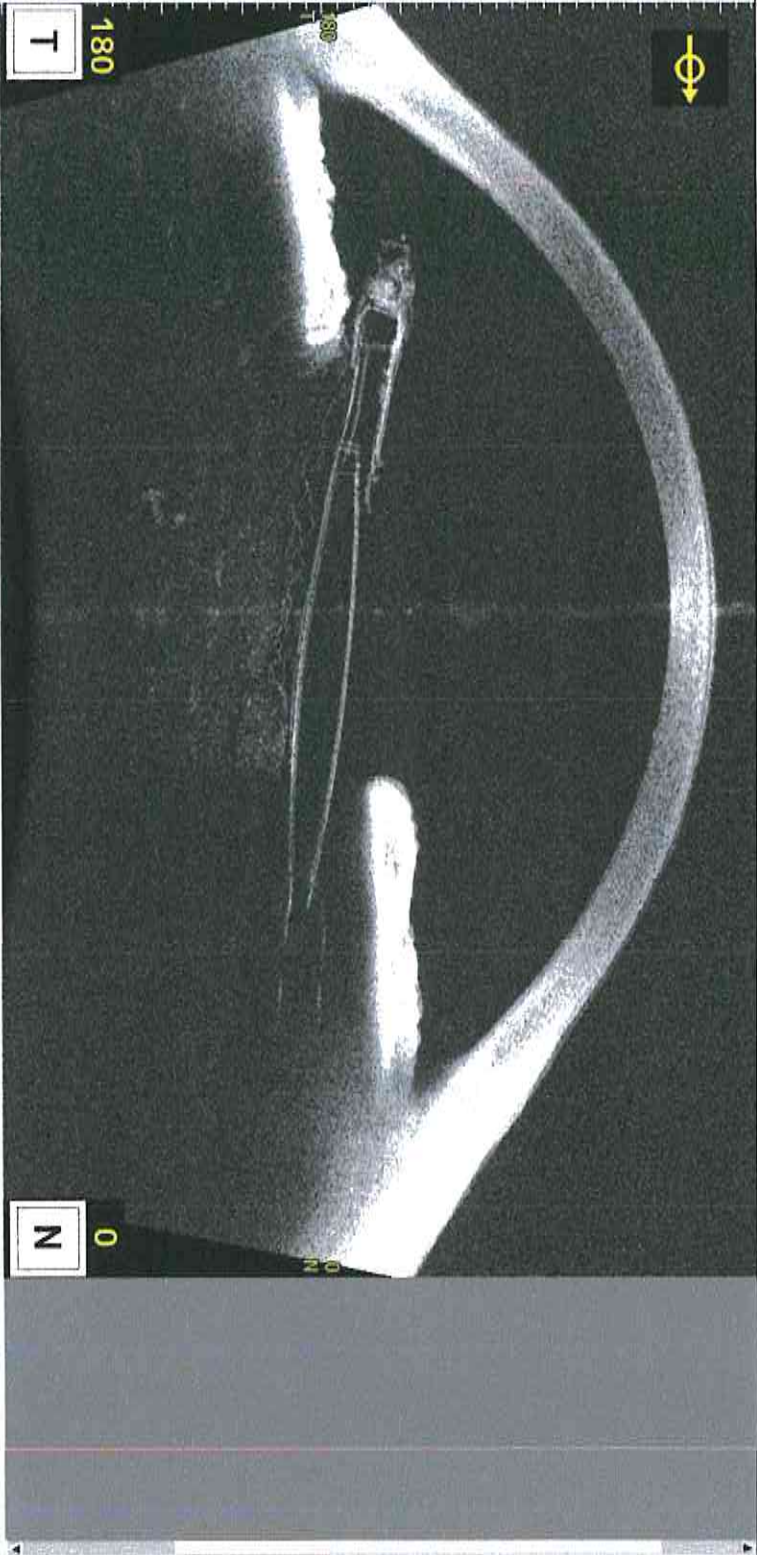
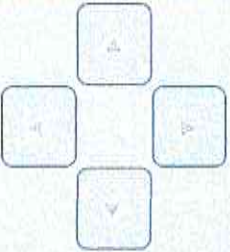


Exam Date: 12/Sept./2023 15:56:50

Comment: Trauma bulbare contusivo



- SS-Left
- AR-Left
- SS-Right
- AR-Right
- Lens-F



180° (Temporal)

	500um	750um
AOD [mm]	---	---
ARA [mm ²]	---	---
TISA [mm ²]	---	---
TIA [°]	---	---

180° - 0°

CCT [um]	---
ACD[Endo.][mm]	---
LV [mm]	---
LT [mm]	---
ACW [mm]	---

0° (Nasal)

	500um	750um
AOD [mm]	---	---
ARA [mm ²]	---	---
TISA [mm ²]	---	---
TIA [°]	---	---

Clinic Info.: OCULISTICA OSP. MORGAGNI FORLI /

DIRETTORE DR. G. COSTA