

Caso 5

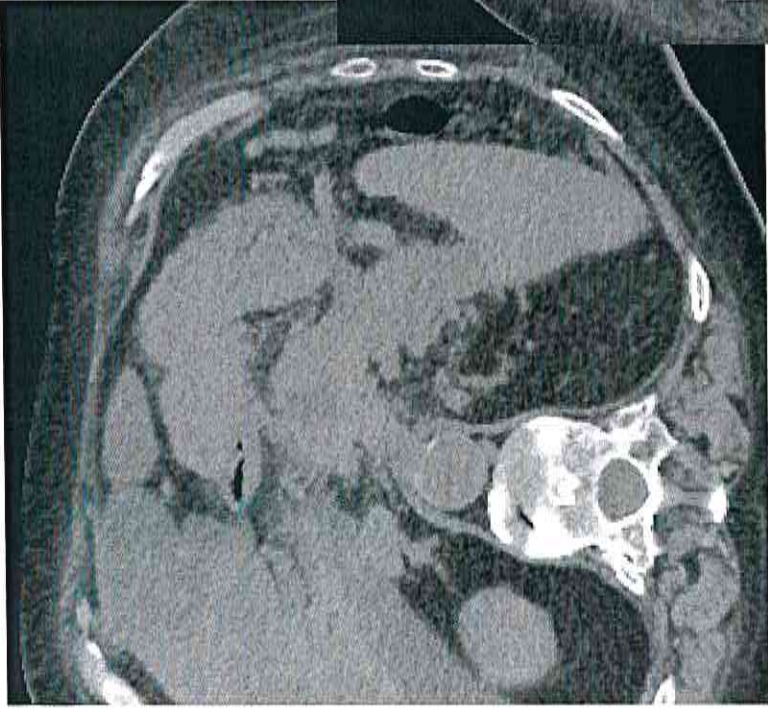
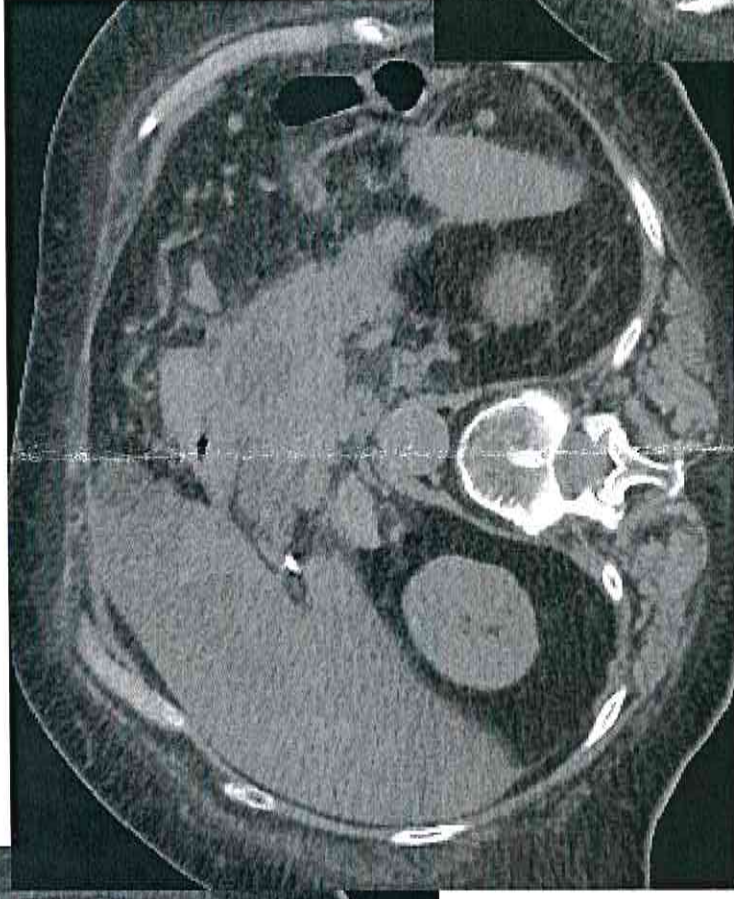
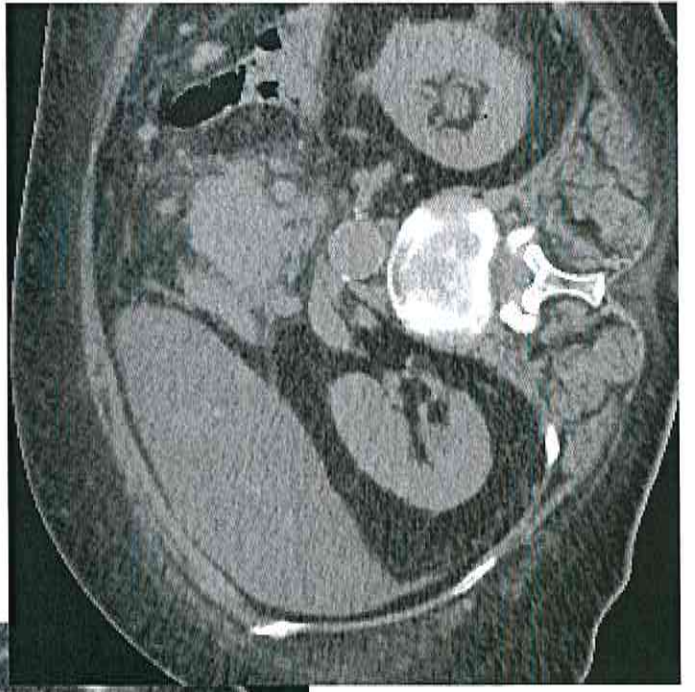


Donna di 76 aa affetta da depressione; giunge in PS per comparsa di dolore all'addome superiore continuo e non collegato ai pasti; calo ponderale di 25 Kg negli ultimi mesi, in obesità e diabete mellito.

Esami di laboratorio all'ingresso nella norma.

Esegue ecografia addominale che riscontra alcune lesioni epatiche di ndd; non esplorabile la regione pancreatica per l'habitus della paziente

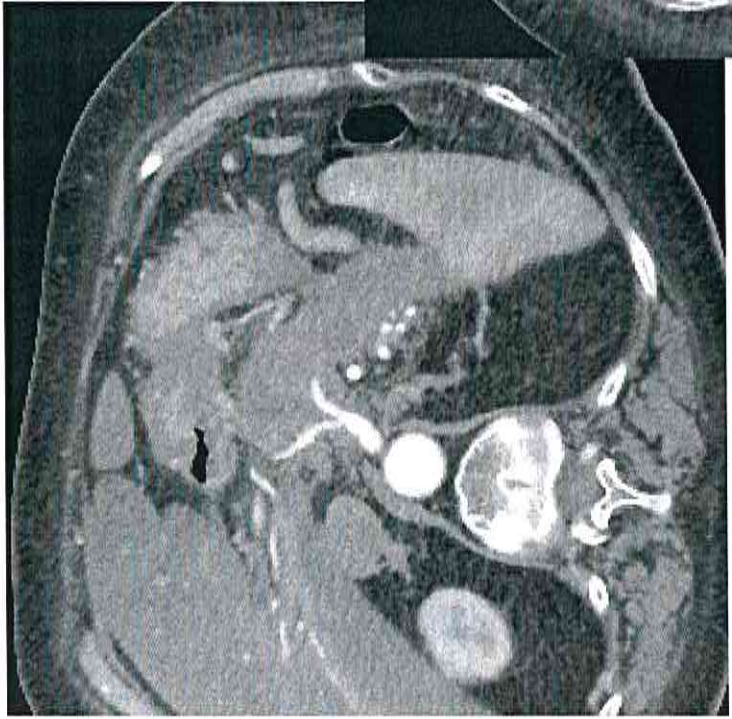
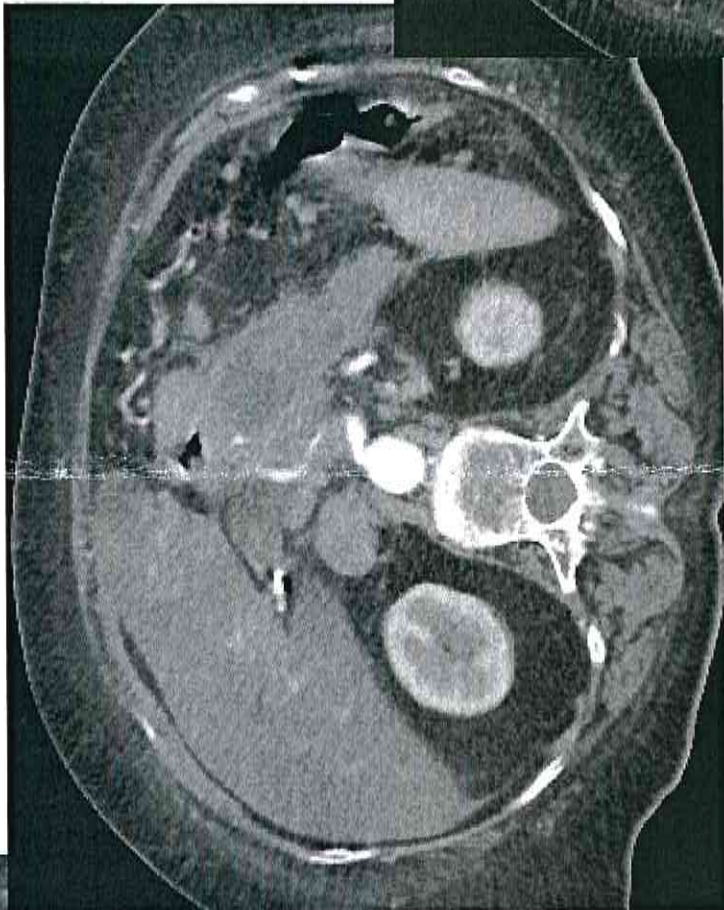
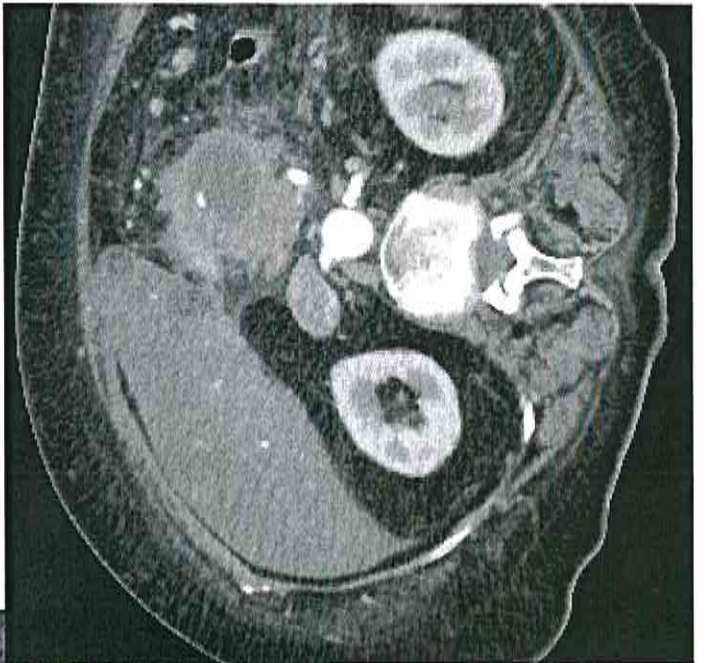
Viene richiesta TC addome senza e con mdc ev.



Caso 5

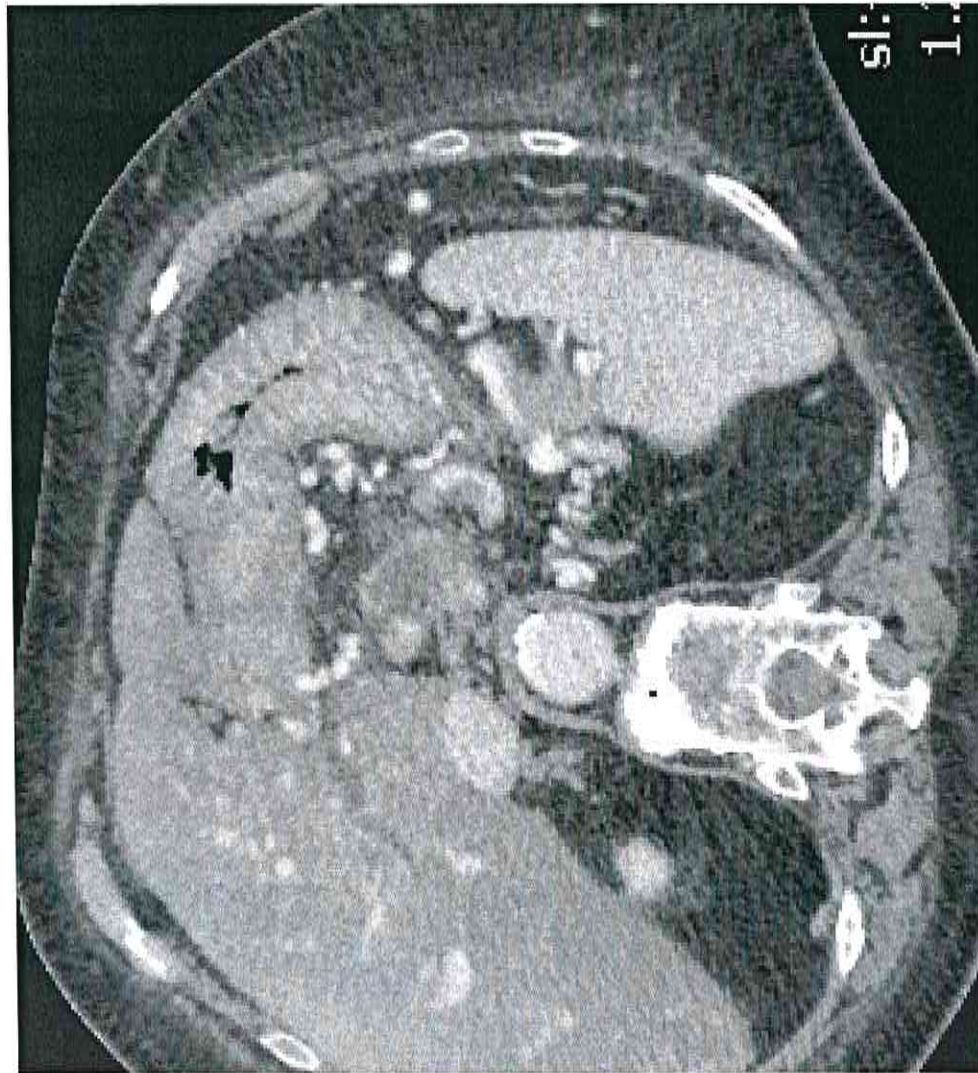
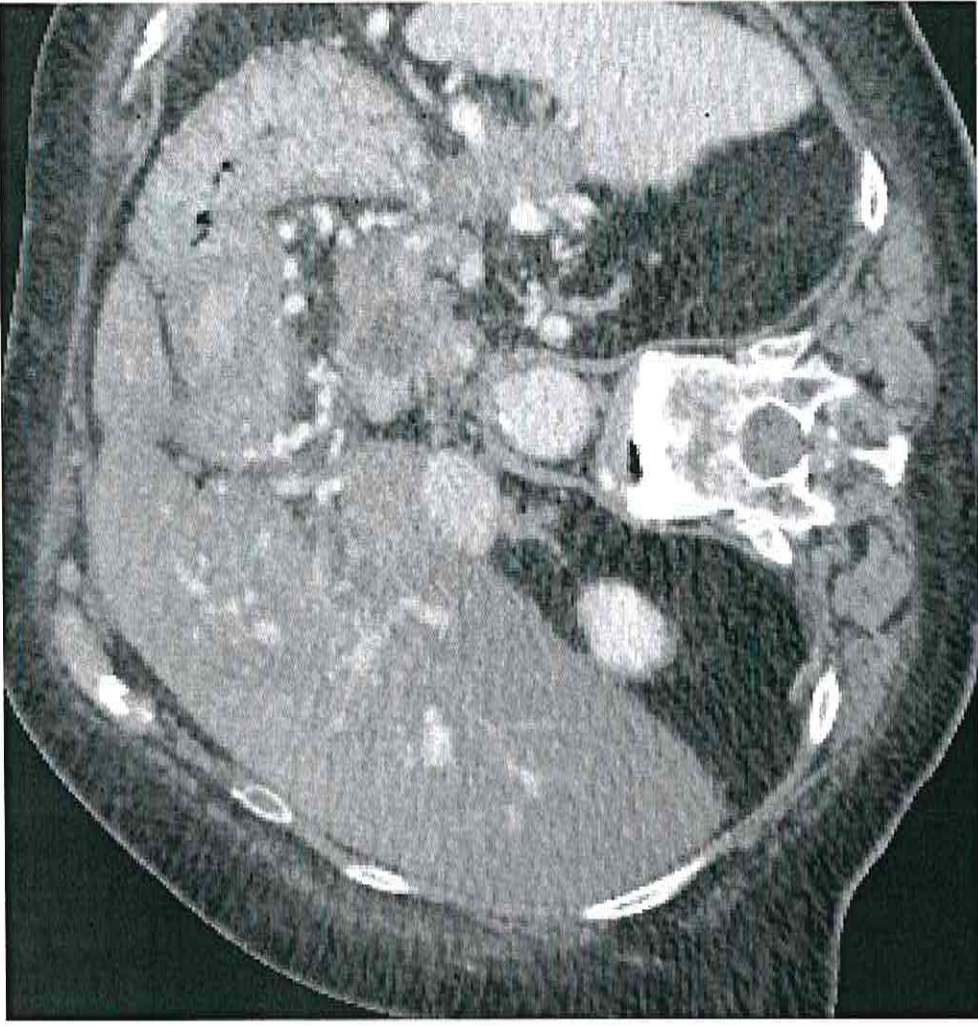


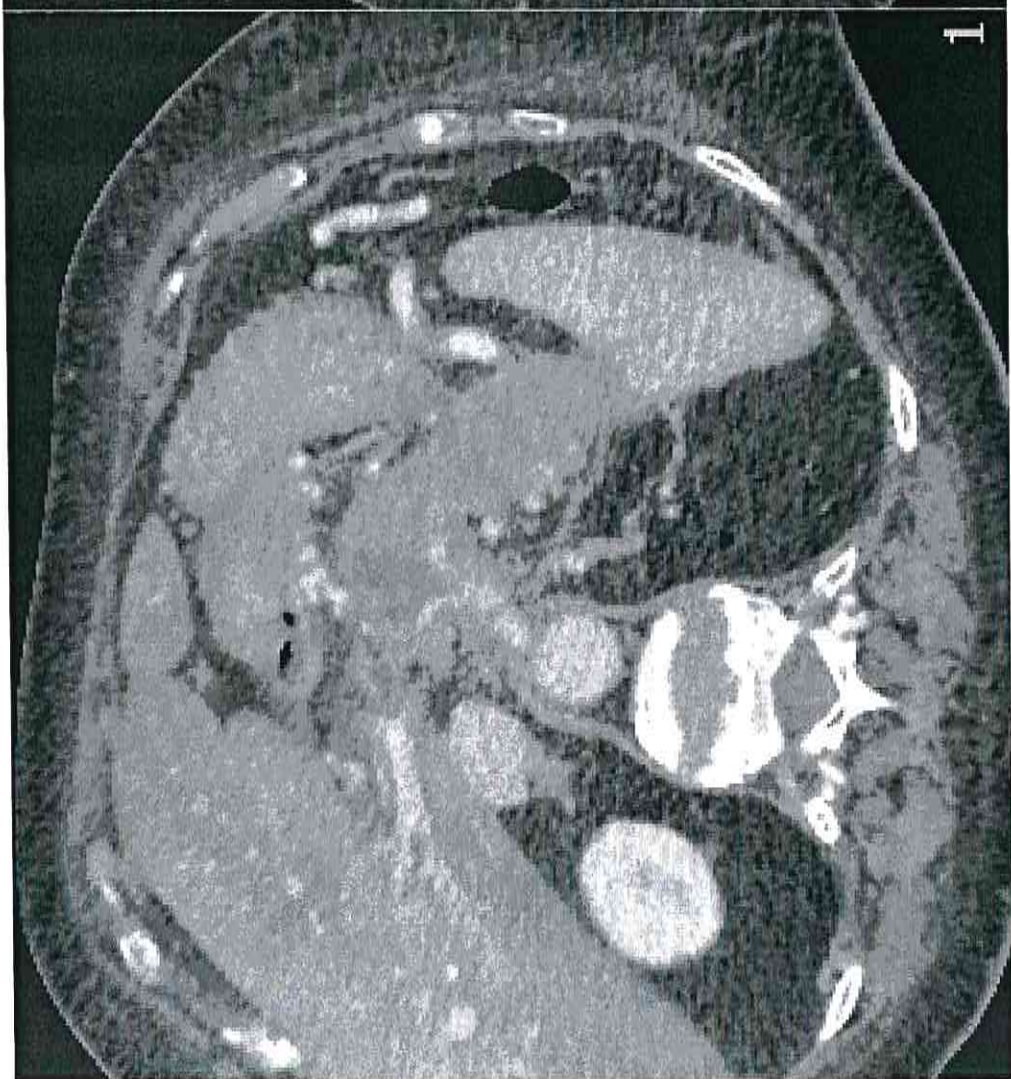
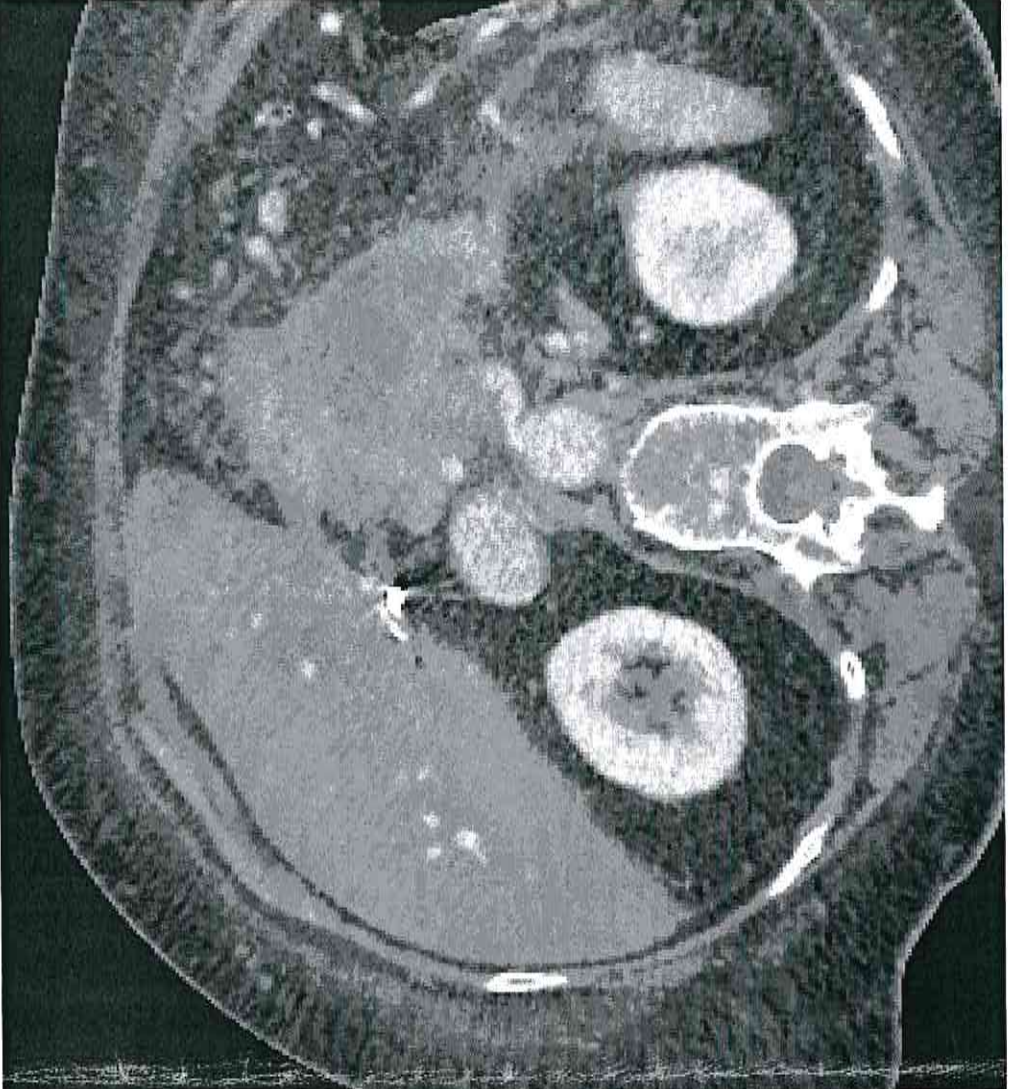
Caso 5



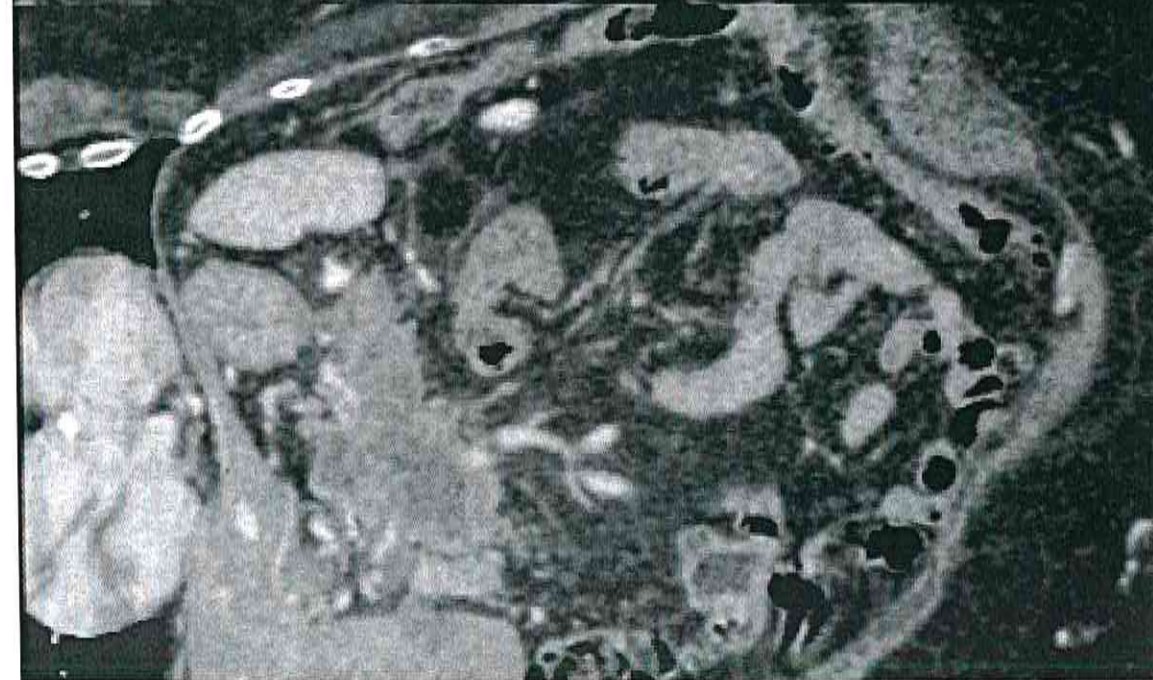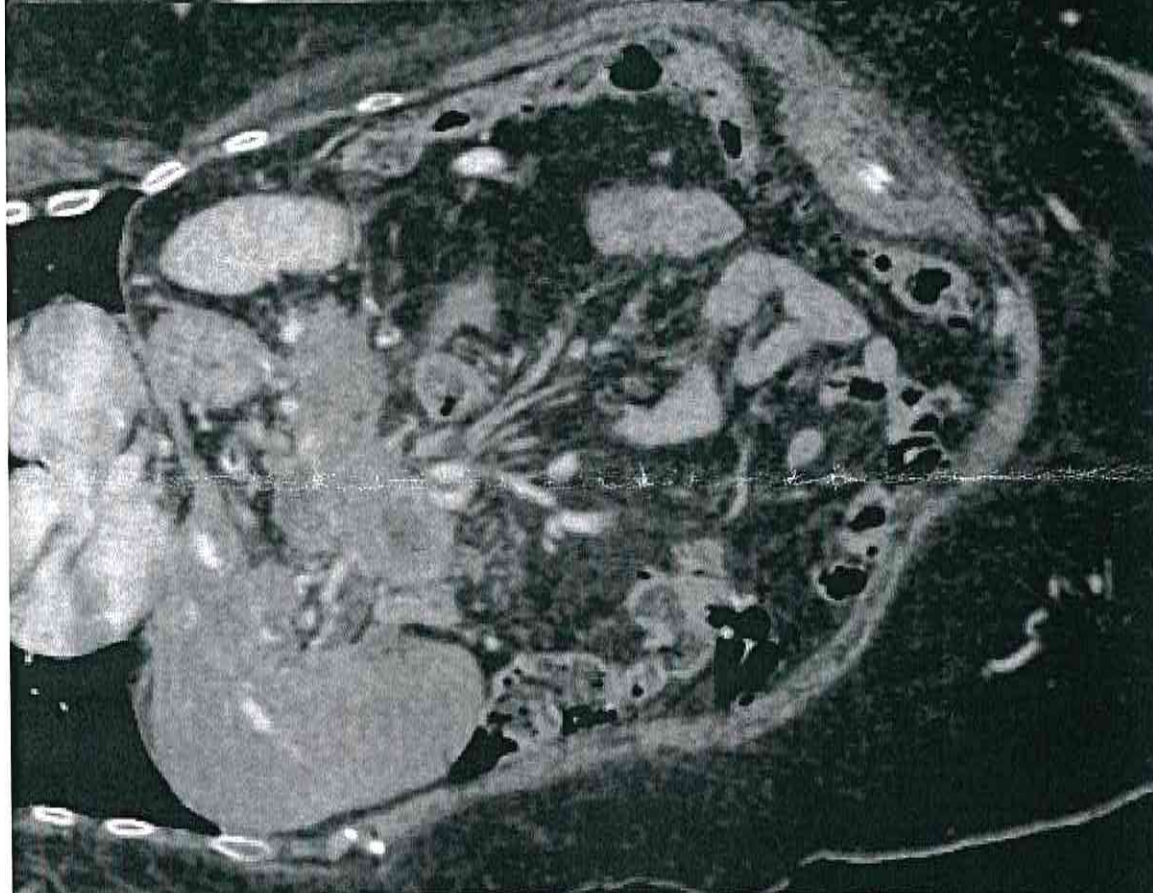
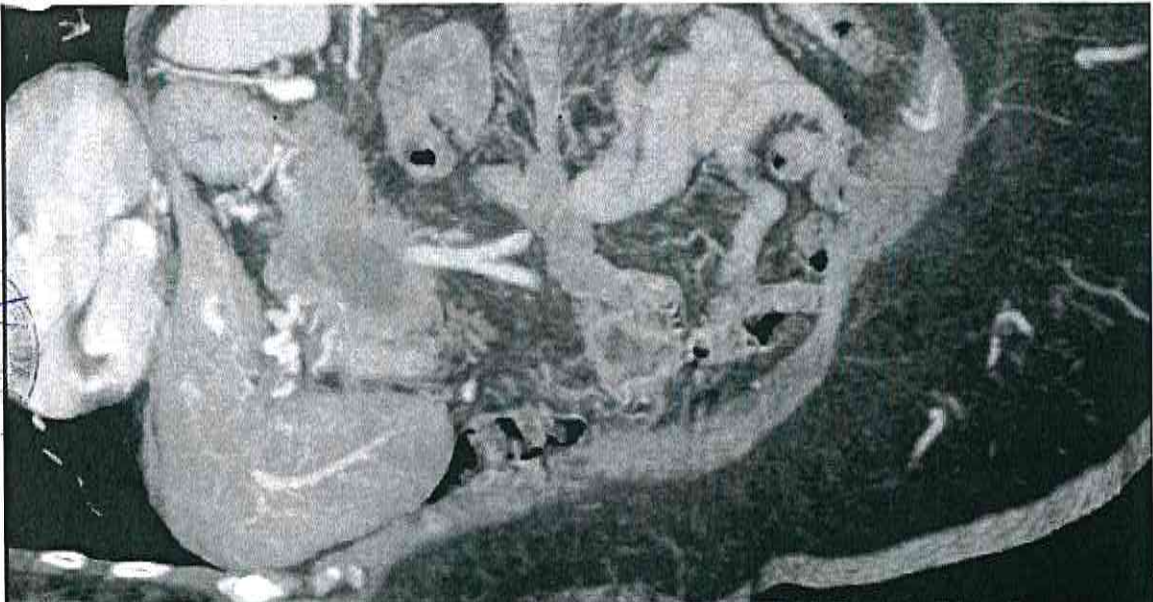


CASO 5





CASO 5



Handwritten signature

CASO 5



CASO 5

