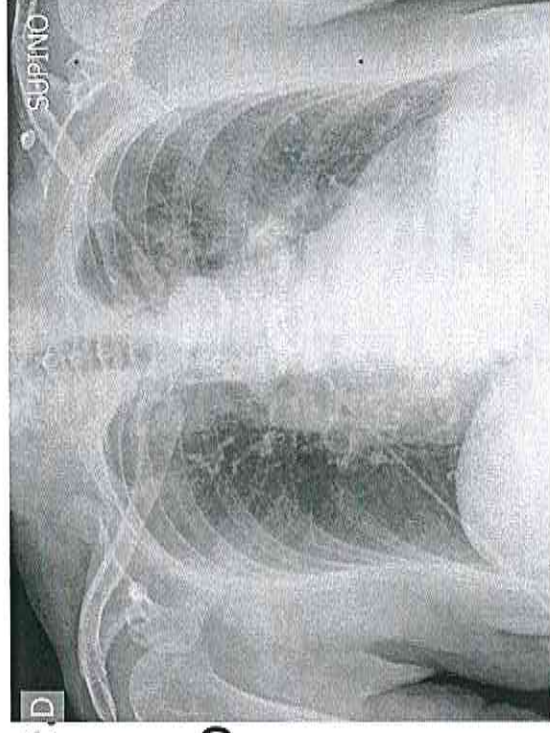


Caso 1

Donna di 77 aa; giunge in PS per dispnea da sforzo, edemi declivi ed iperpiressia (39°). Anamnesi patologica remota: episodi di scompenso cardiaco recidivanti.

Esegue Rx Torace AP supino ed ecografia addominale.



Rx Torace mostra versamento pleurico basale sinistro con strie parenchimali e segni di scompenso

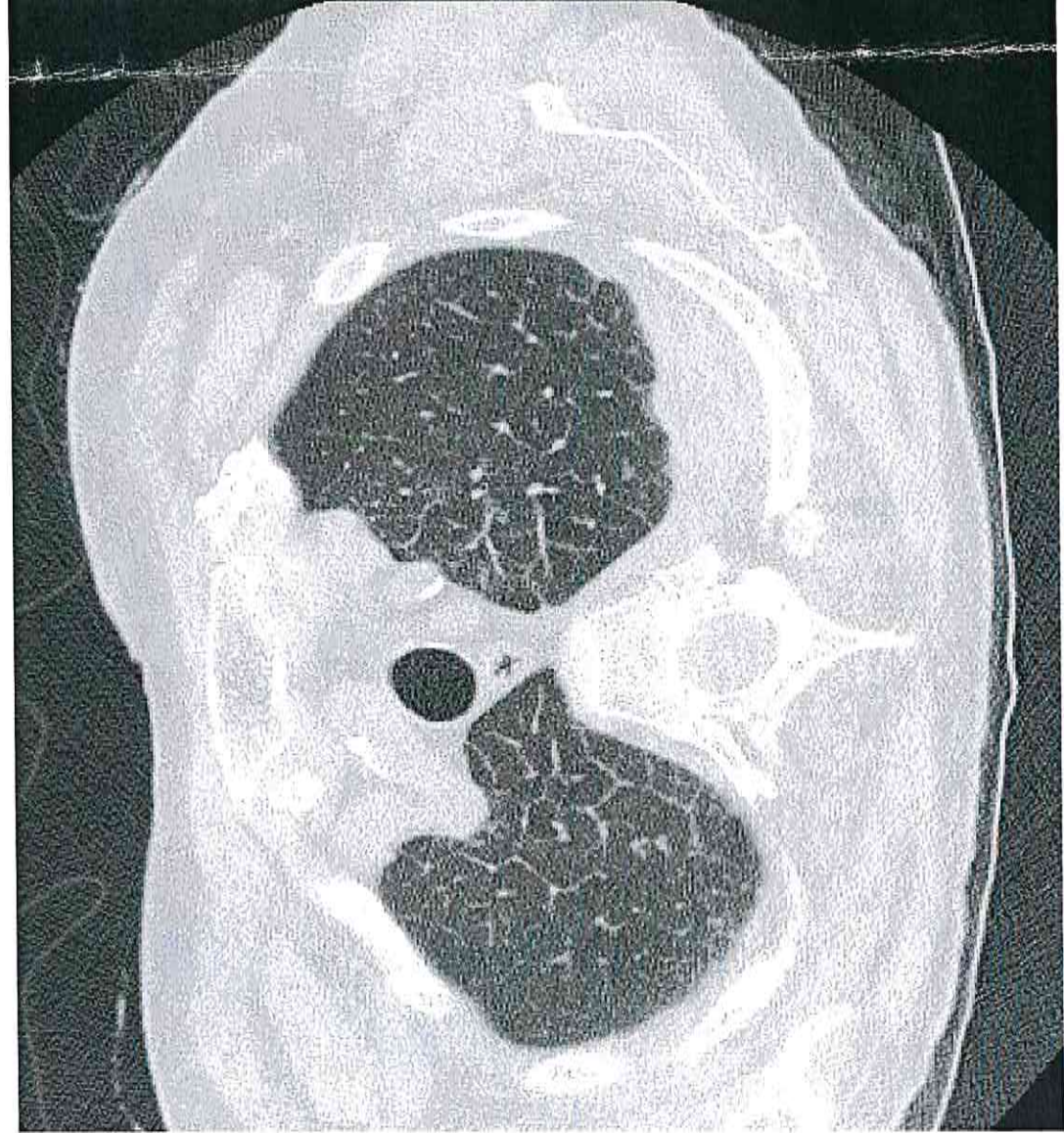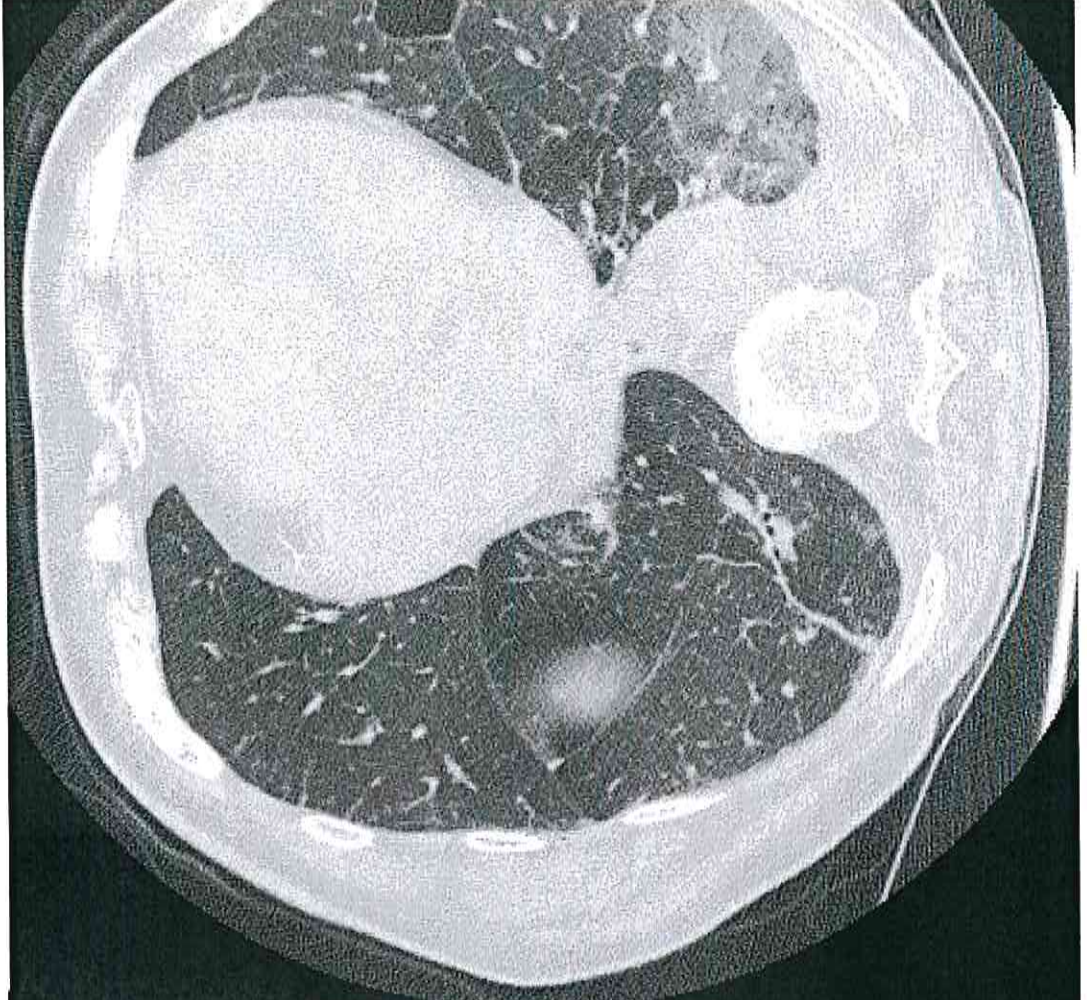
Ecografia addome mostra versamento pleurico bilaterale ed addensamento bsa sinistra

Viene richiesta TC torace senza e con mdc ev.



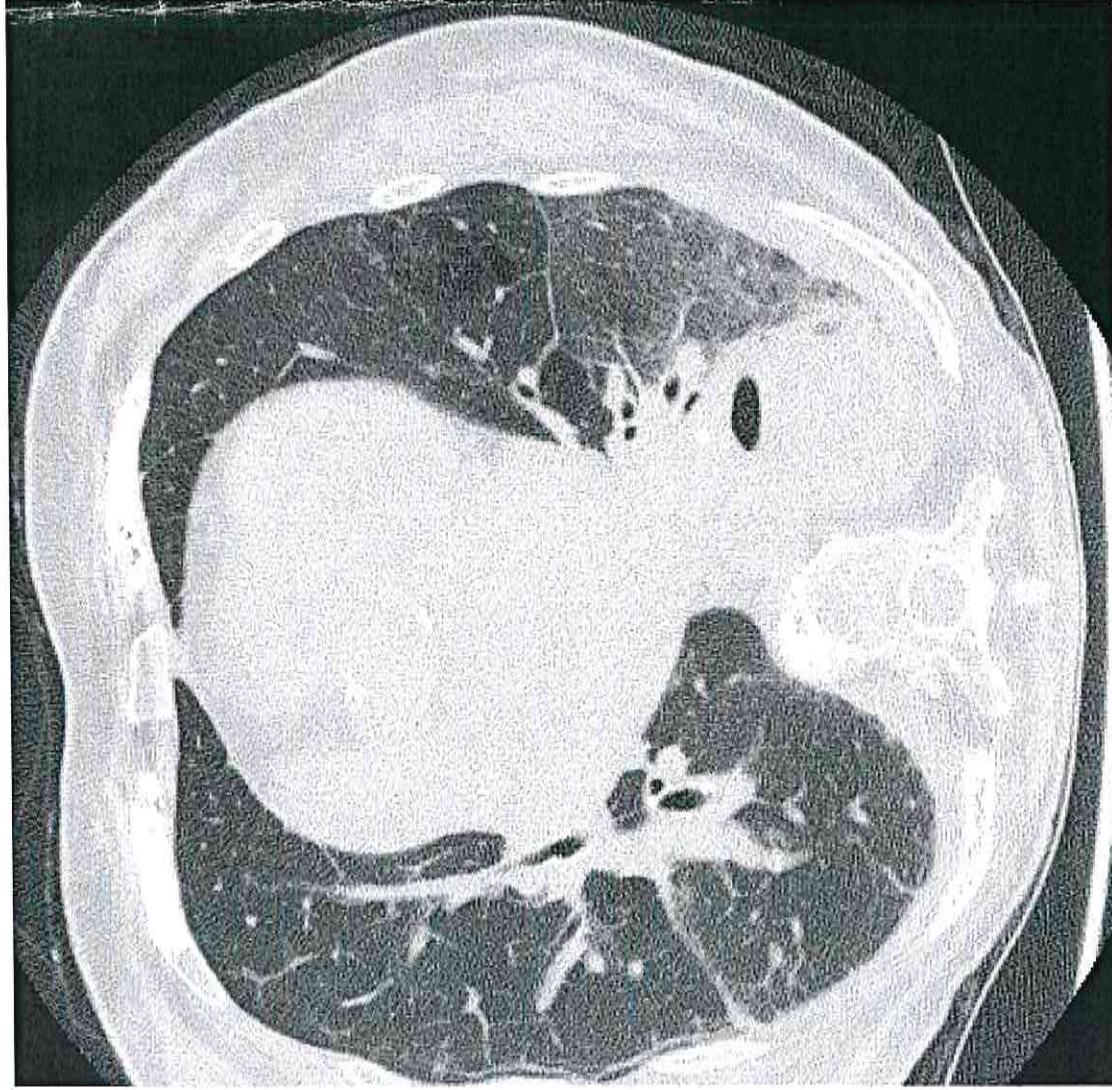
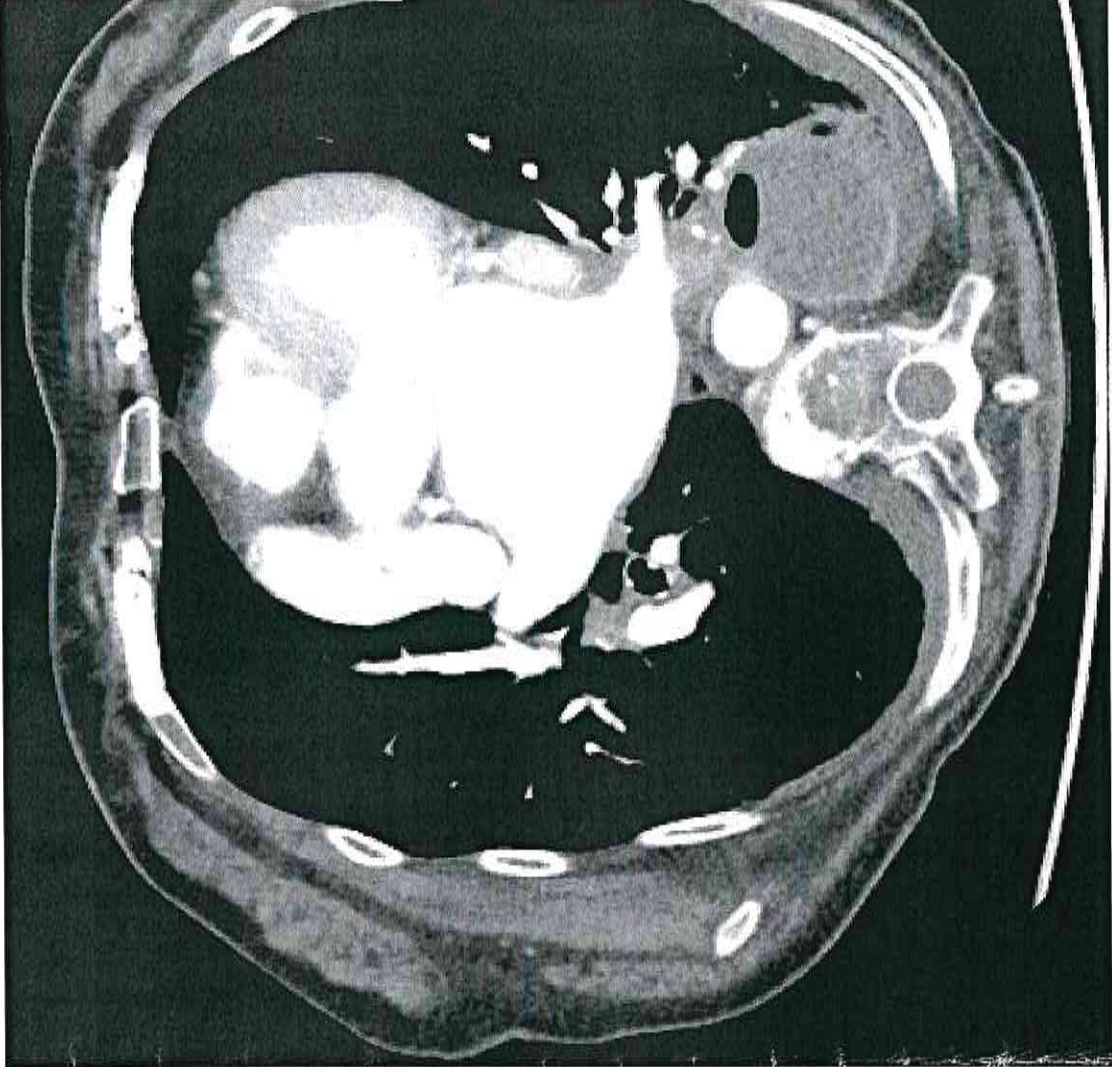


CASO 1

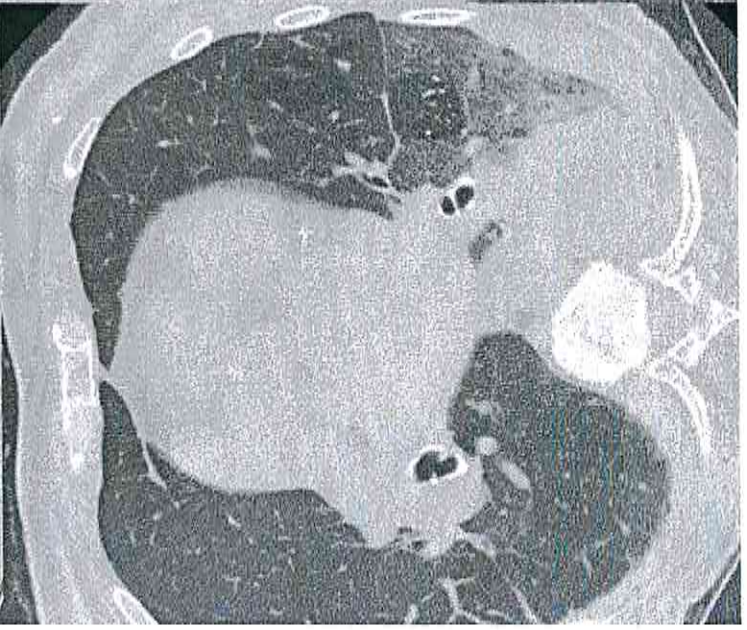
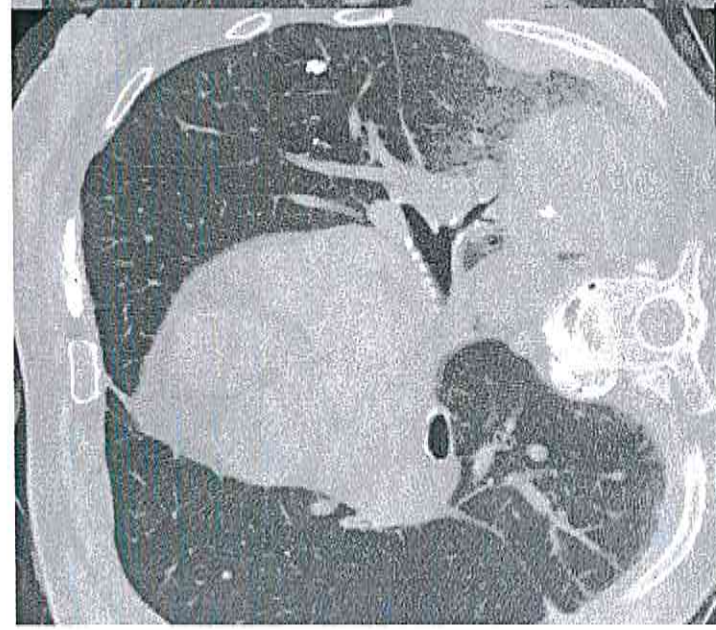
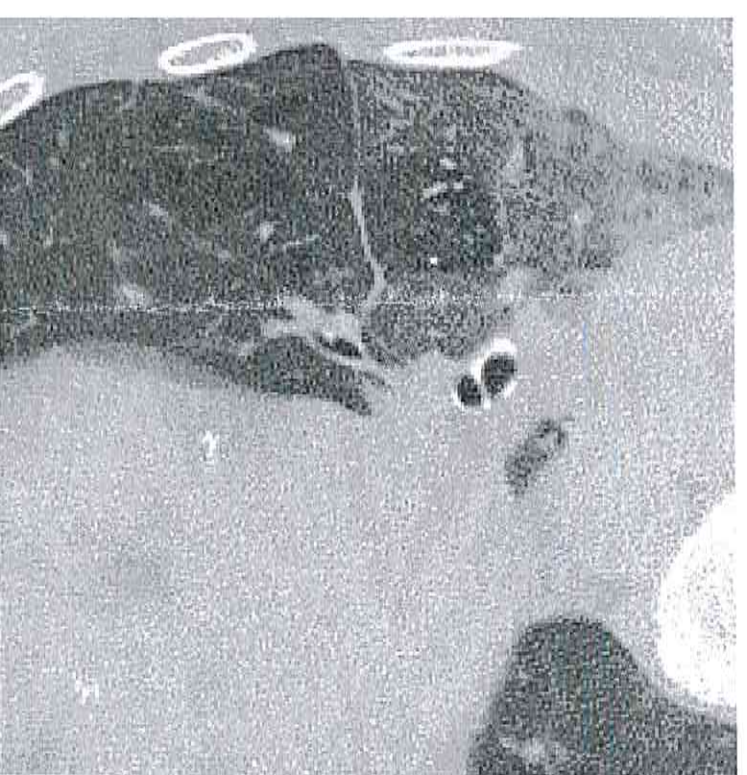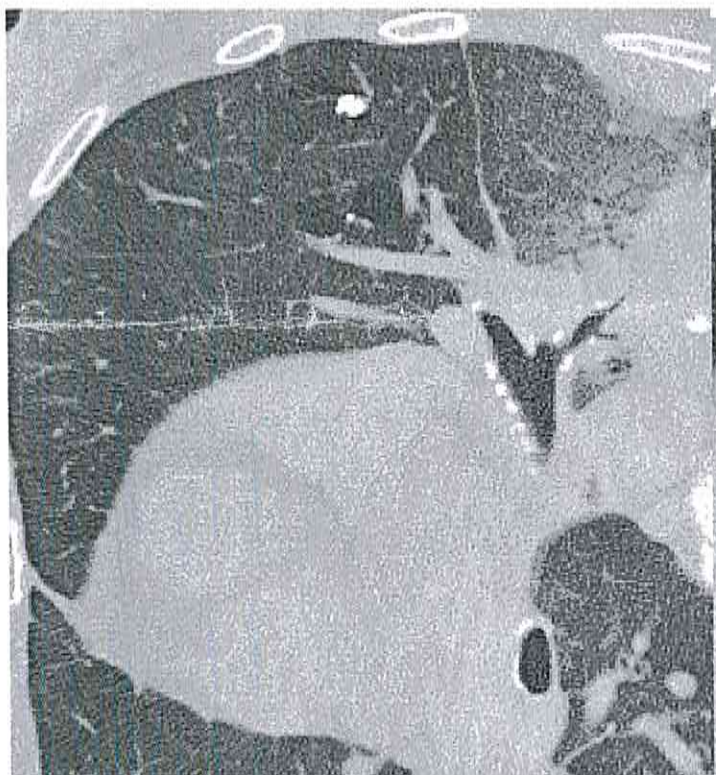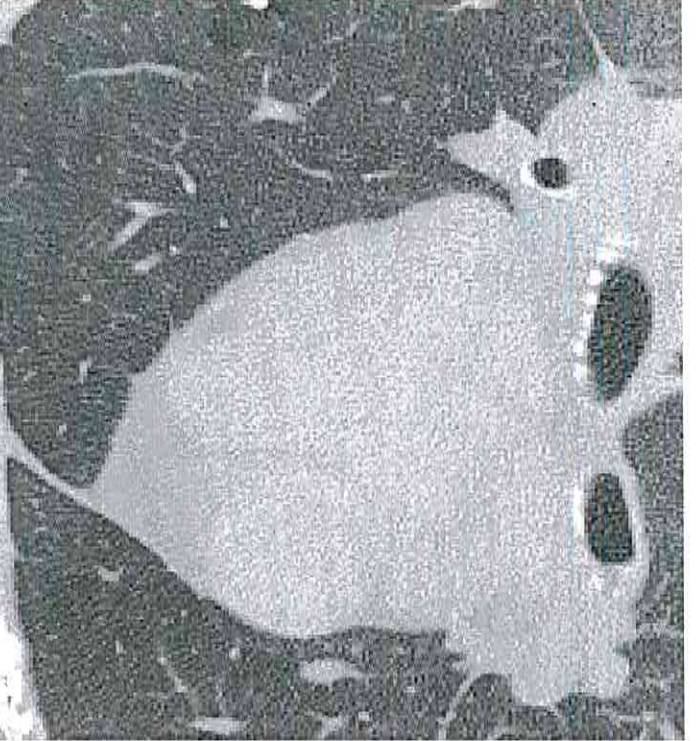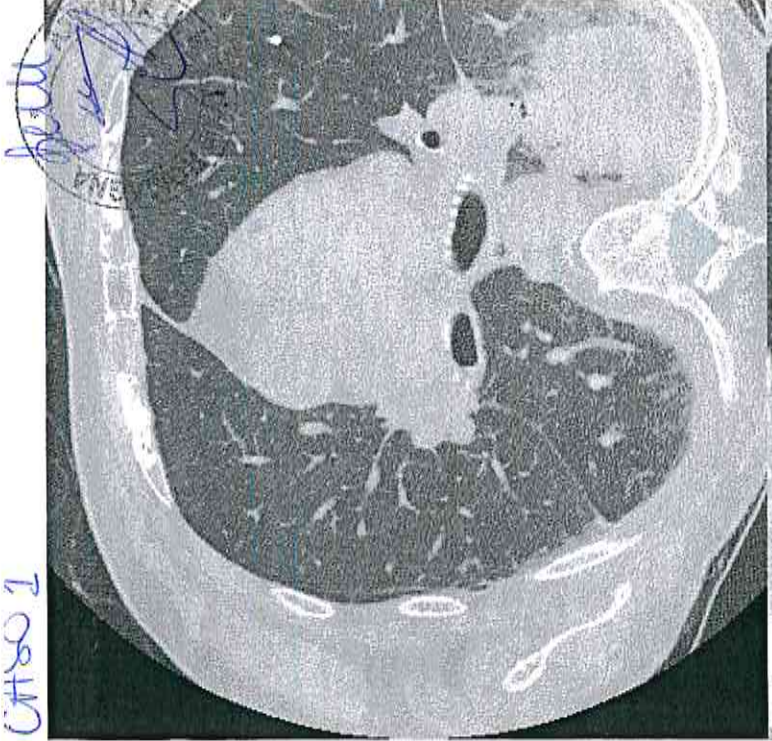


ASST L. S. L. delle ROMAGNE
S. L. delle ROMAGNE
ASST L. S. L. delle ROMAGNE

CASO 1



Case 1



CASO 1

