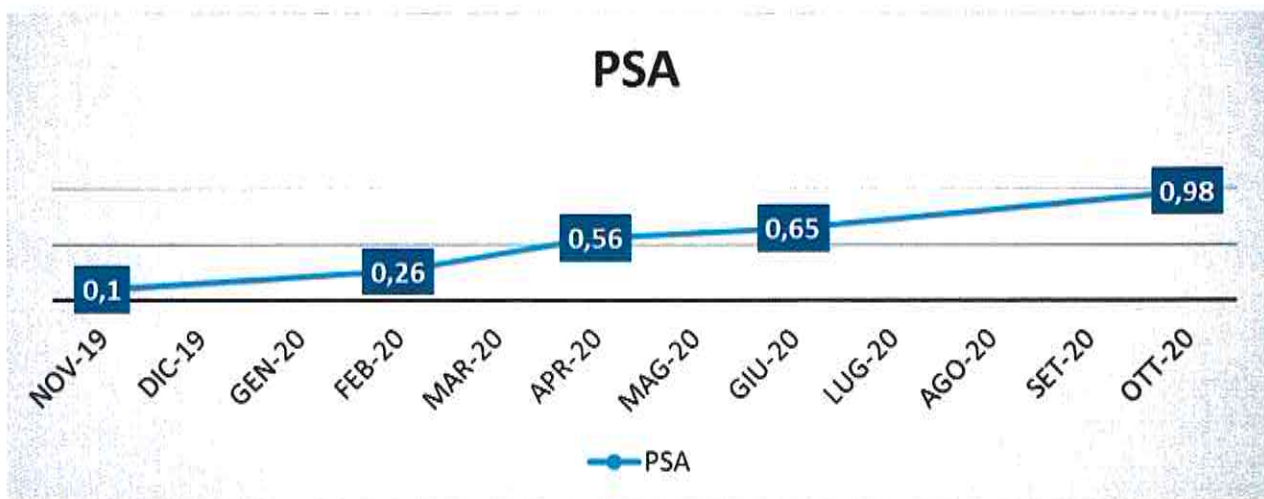


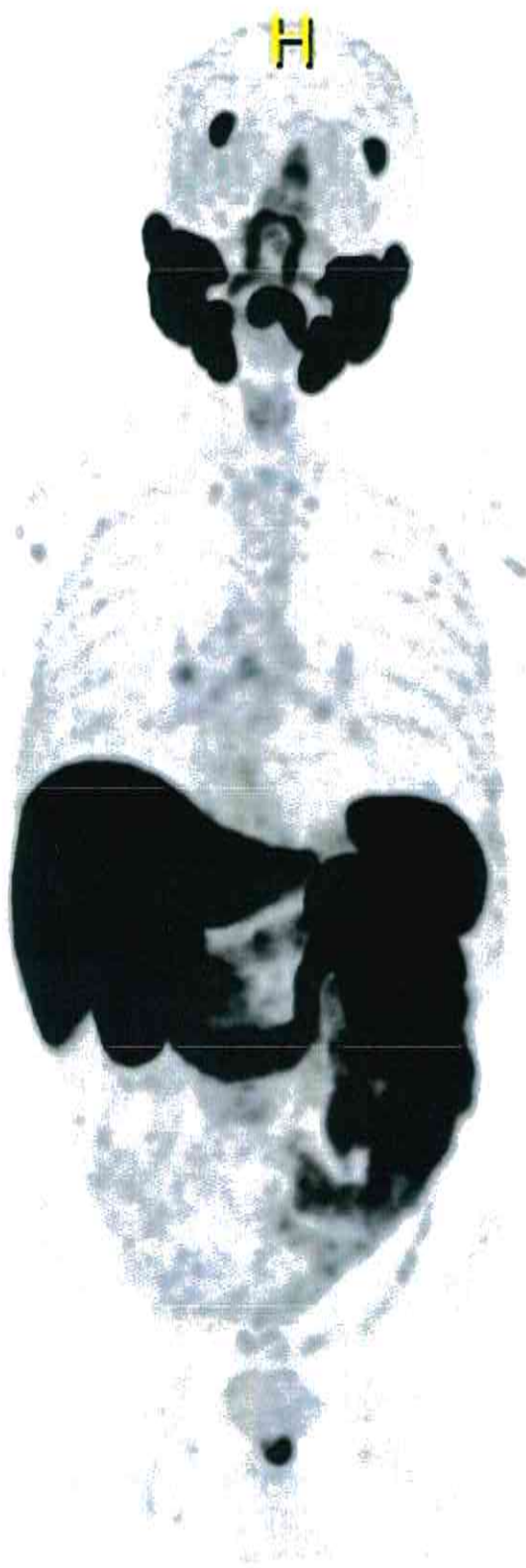# PROVA PRATICA 1

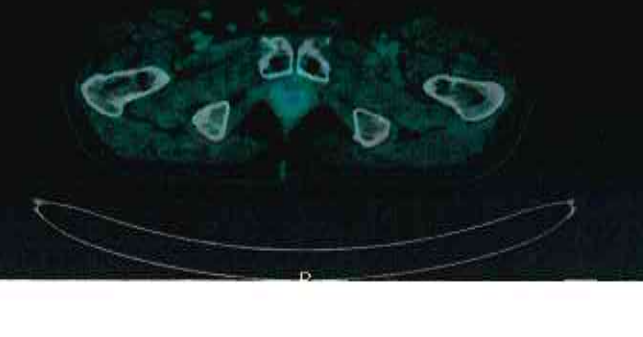
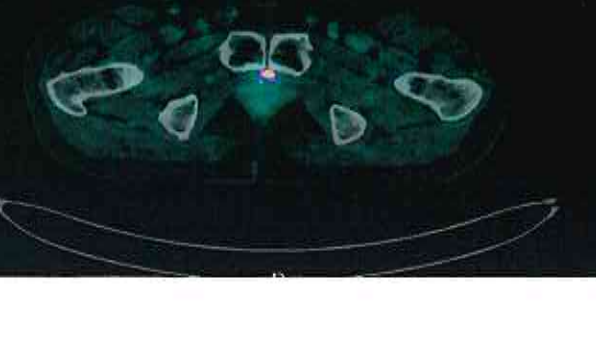
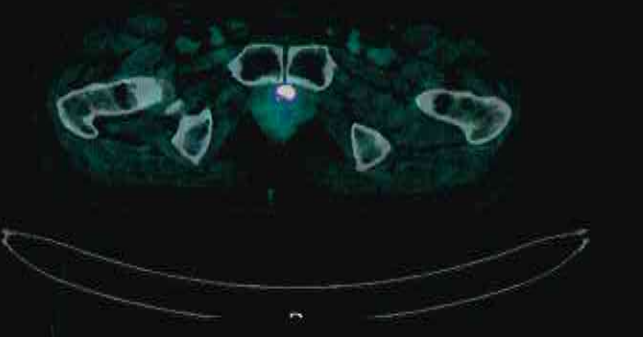
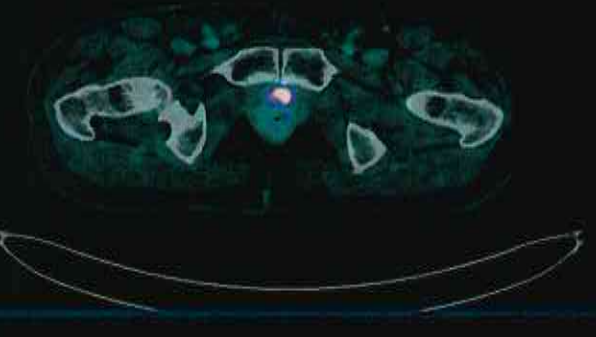
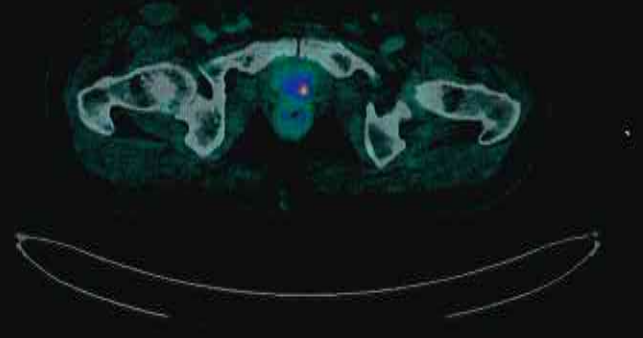
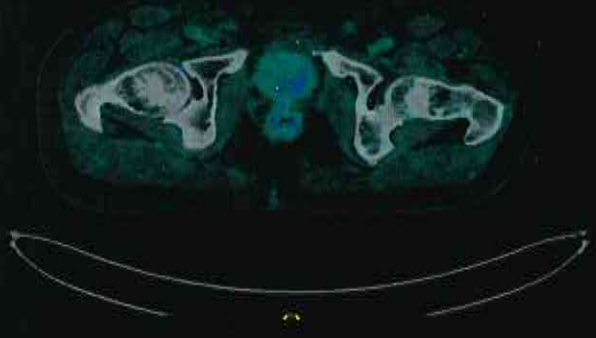
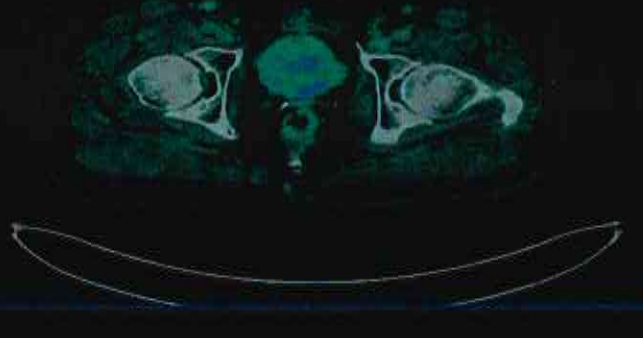
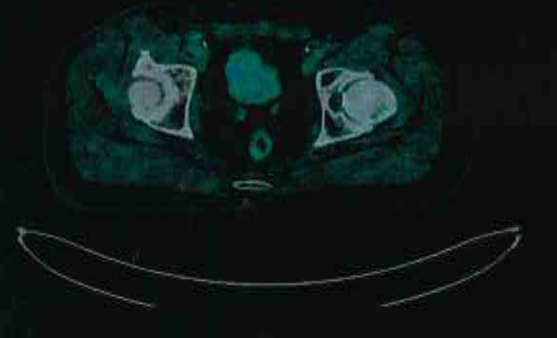
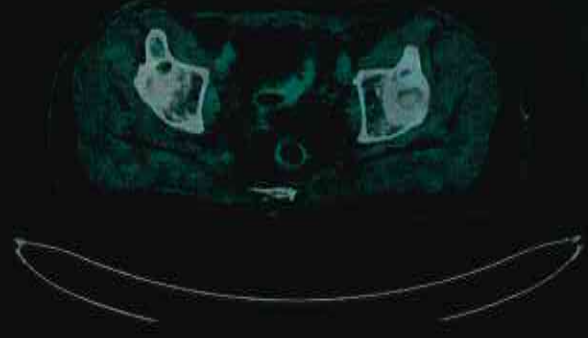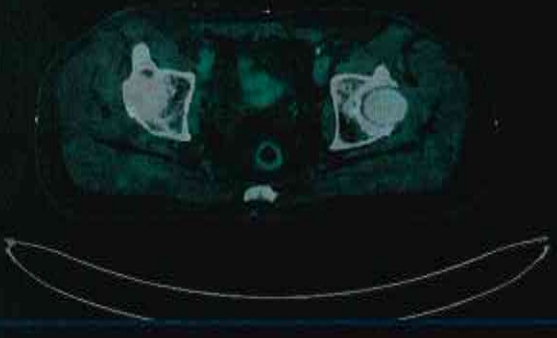
P.V. 63 anni

## ANAMNESI

- 2012: Prostatectomia + Radioterapia su pelvi e linfonodi (G.S 4+3; pT3bR0).
- 2017: a seguito del riscontro di recidiva di malattia a livello dell'anastomosi vescico-uretrale, inizia BAT (casodex + enantone 3,75). Ultima somministrazione 1/4/2019.
- Ottobre 2020 valore PSA pari a 0,98 ng/ml







## **PROVA PRATICA 2**

**T.G. 75 anni**

### **ANAMNESI**

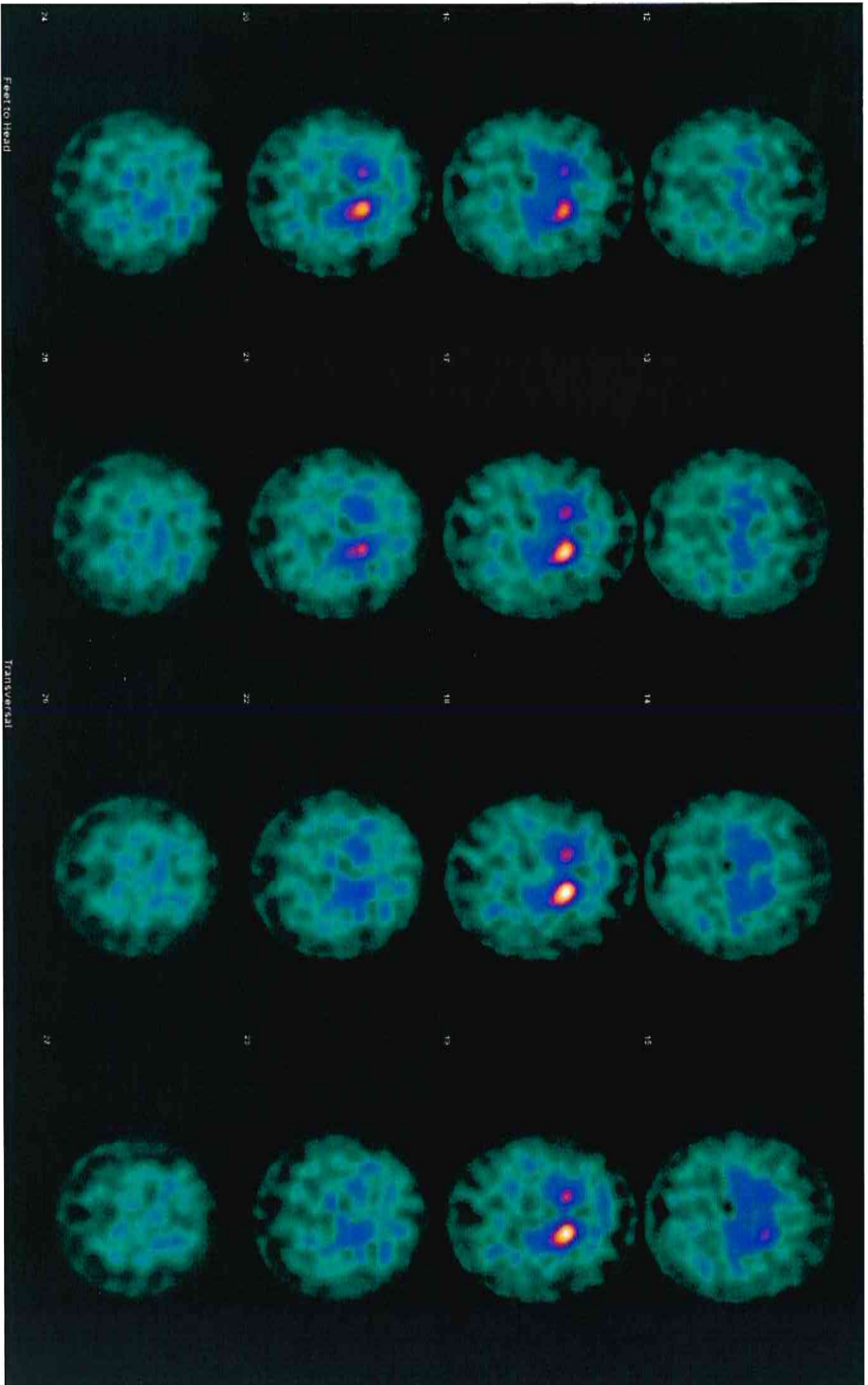
Valutato da Neurologo in marzo 2022 in merito a presenza, da un paio di mesi, di tremore AS ssx.

Padre con tremore.

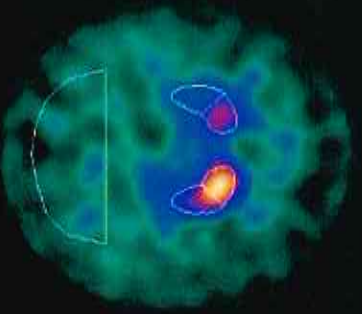
All'anamnesi patologica prossima: Infezione da coronavirus in febbraio 2022.

Assume Rytmonorm per riferite tachicardie non meglio precisate.

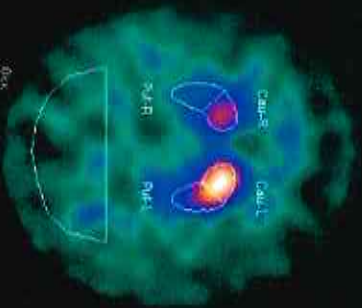
EON: vigile, orientato, collaborante. Facies ipomimica. Minimo tremore a riposo arti di sx. Lieve ipertono AS sx dopo manovre di slatentizzazione. Lieve ipocinesia al finger tapping a sx. Riferite sfumate difficoltà mnesiche e maggiore irritabilità. Probabile ipoacusia.



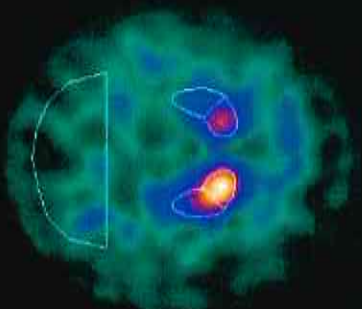
Slice 1



Slice 2



Slice 3



**Mean Counts**

	Cau-L	Cau-R	Put-L	Put-R	Occ
Slice 1	121.0	87.5	89.5	60.2	33.7
Slice 2	130.0	89.8	91.6	57.7	33.2
Slice 3	126.0	87.4	89.2	57.4	33.0
Average	126.3	88.2	90.1	58.4	33.3

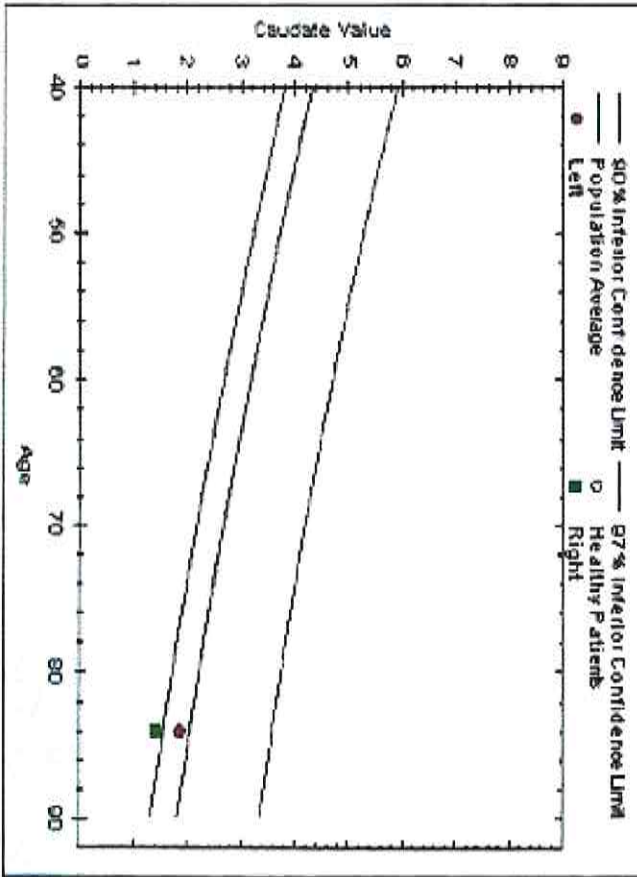
**Ratios**

StriatL / Occ	3.20
StriatR / Occ	2.15
Caud-L / Occ	3.76
Caud-R / Occ	2.65
Put-L / Occ	2.71
Put-R / Occ	1.76
PutL/CaudL	0.72
PutR/CaudR	0.66

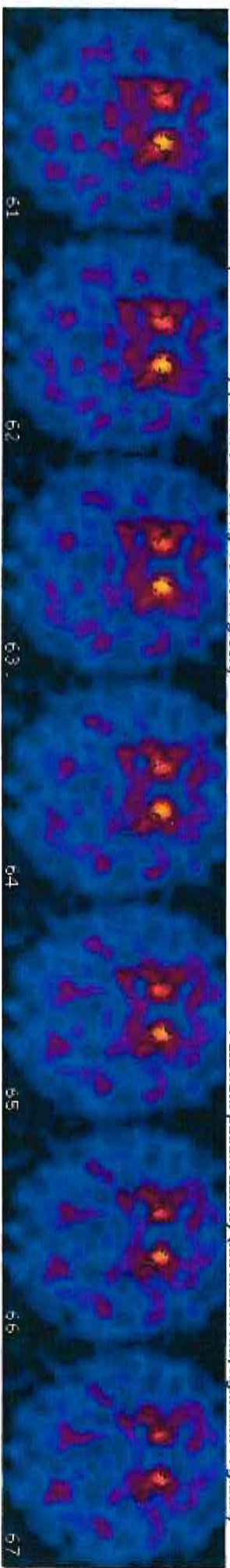
Date: 3/9/2019

Counting:

	Left	Right
Caudate Counting	4.80	4.06
Caudate - Background/Background	1.86	1.42
Putamen Counting	2.95	2.95
Putamen - Background/Background	0.76	0.76
Putamen/Caudate	0.41	0.54

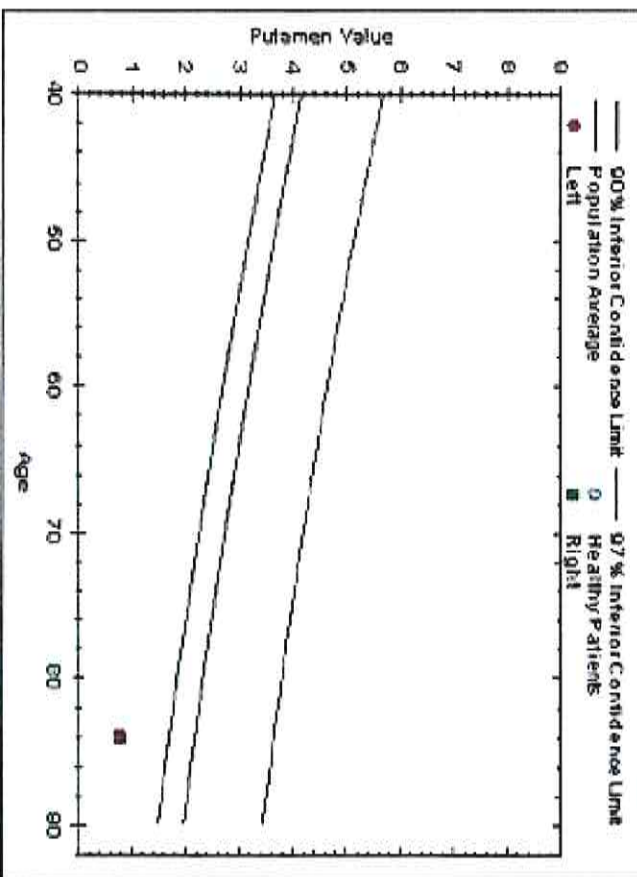


Caudate: patient activity (left side in red, right side in green)



Asymmetry: Caudate activity is 27% higher on Left hemisphere  
Putamen activity is 0% higher on Left hemisphere

	Background
Total Number of Voxels	9169.70
Total Counting	15387.13
Counting Mean in Background Area	1.68



Putamen: patient activity (left side in red, right side in green)

## PROVA PRATICA 3

Paziente maschio di 83 anni.

Passaggio recente in DEA per aritmia extrasistolica e dispnea; alla RX del torace ombra cardiomediastinica di dimensioni ai limiti superiori di norma per aterosclerosi. Riscontro all'ECG di blocco di branca destra; PAOS 160/80 e accenno a subedemi declivi.

All'eco-cardio marcata ipertrofia concentrica con lieve riduzione della funzione sistolica (FE 40%), in presenza di acinesia della parete posteriore e della parete anteriore basale media. Incremento della rifrangenza prevalentemente a carico del setto (patologia infiltrativa?). Disfunzione diastolica di III° grado ed atrio sinistro marcatamente dilatato.

Alla RM cardiaca ipertrofia concentrica del ventricolo sinistro con diffusa ipocinesia e funzione sistolica ridotta.

